



Abstract No. : 24

Abstract Title: A Pictorial Review of Cardiac MRI Features in Post COVID-19 Vaccine Acute Myocarditis

Authors: Dr. CT Wang, Dr. HL Tsui, Dr. PY Chu, Dr. YH Hui, Dr. YW Hon
 Affiliation: Department of Radiology & Organ Imaging, United Christian Hospital



Background

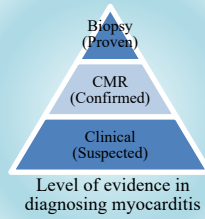
- Post COVID-19 vaccine acute myocarditis was reported since commencement of vaccination program in Hong Kong. Cardiac MRI (CMR) played a key role in diagnosis.

Purpose and Method

- To review myocardial injury pattern after COVID-19 vaccine on CMR.
- Patients under 18 years old with clinically suspected post COVID-19 vaccine acute myocarditis were included between 1/1/2021 and 28/2/2023. CMR images were reviewed with reference to Lake Louise Criteria 2009.

Lake Louise Criteria 2009

| | |
|---------------------|--|
| Main criteria | 1. Edema → Regional or global signal intensity (SI) increase in T2-weighted images. |
| | 2. Hyperaemia/ Capillary Leak → Regional or global early Gadolinium enhancement in T1-weighted images. |
| | 3. Necrosis/ Fibrosis → At least one focal lesion with non-isoaemic regional distribution on late Gadolinium enhancement . |
| Supportive criteria | 1. Left ventricular dysfunction 2. Pericardial involvement |



- ❖ If **at least 2 out of 3** main criteria present → **consistent with acute myocarditis**
- ❖ If **only 1 out of 3** main criteria present → still suggestive of acute myocarditis in **appropriate clinical scenario and supportive criteria**

Results & Conclusion

| | |
|---|---|
| Gender | 12 male, 3 female |
| Age (Mean) | 12-17 years old (14.7 years old) |
| Time interval from vaccination to presentation (Mean) | 0-13 days (2.9 days) |
| No. of patients with elevated cardiac enzymes | Troponin T: 7/15 (46.7%) Creatinine Kinase: 3/15 (20%) |
| Type of vaccine | BioNTech : 15/15 (100%) |

Table 1. Characteristics of the 15 patients with clinically suspected post COVID-19 vaccination myocarditis

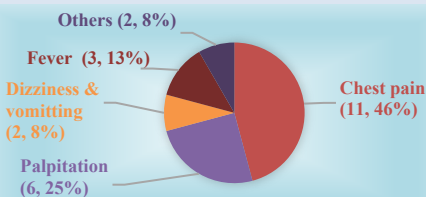


Fig 1. Symptoms of the 15 patients after BioNTech vaccine.




Fig 2. 7 out of 15 patients showed CMR features of acute myocarditis.


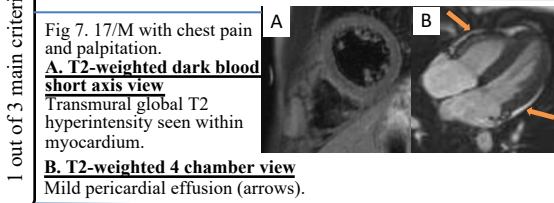
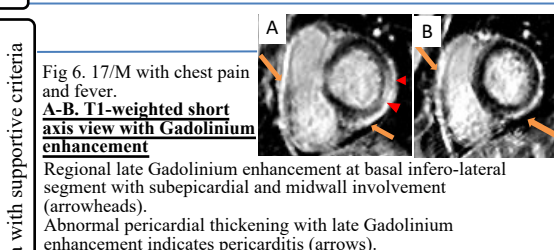
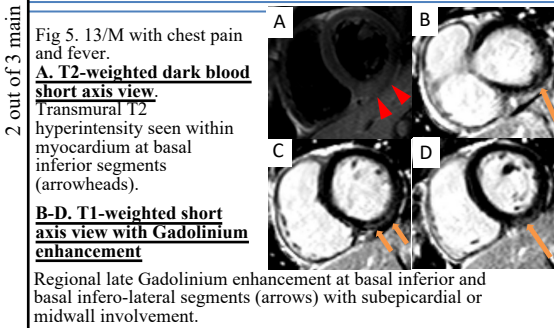
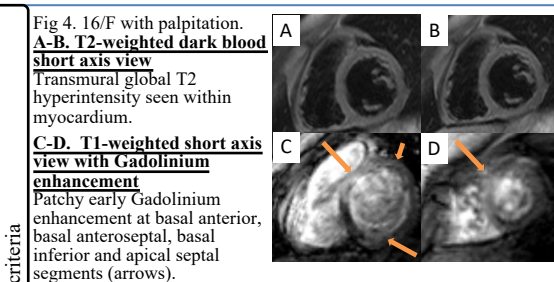


Fig 3. CMR features of the 7 patients with acute myocarditis.

Conclusion
 Recognising **Cardiac MRI** features of **post COVID-19 vaccine myocardial injury pattern** with **clinical and biochemical** evidence of acute myocarditis will facilitate prompt treatment in our paediatric patients.

References: The authors have no conflict of interest to disclose with respect to this presentation.
 1. Fronza, M., Thavendiranathan, P., Chan, V., Karur, G. R., Udell, J. A., Wild, R. M., Hong, R., & Hanneman, K. (2022, September). Myocardial Injury Pattern at MRI in COVID-19 Vaccine-Associated Myocarditis. *Radiology*, 304(3), 553–562. <https://doi.org/10.1148/radiol.212559>
 2. Law, Y. M., Lal, A. K., Chen, S., Čiháková, D., Cooper, L. T., Deshpande, S., Godown, J., Grosse-Wortmann, L., Robinson, J. D., & Towbin, J. A. (2021, August 10). Diagnosis and Management of Myocarditis in Children. *Circulation*, 144(6). <https://doi.org/10.1161/cir.0000000000001001>



2 out of 3 main criteria

1 out of 3 main criteria with supportive criteria