



Abstract No.: 129

Title: **Milder Motor Impairment is Associated with Less Extensive Thalamic Damage in Full-term Children with PVL**

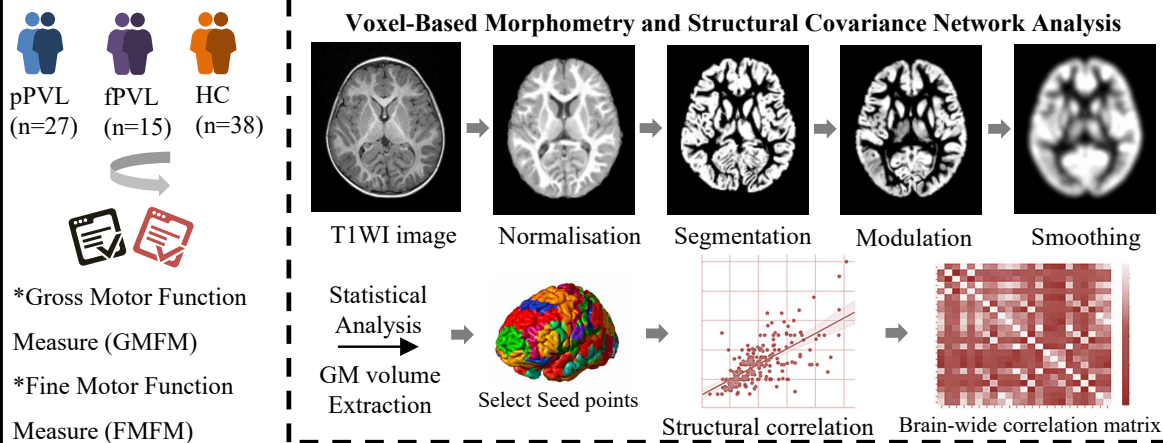
Author(s): Jieqiong Lin, Hongwu Zeng

Affiliation(s): Shenzhen Children's Hospital

Background

- Periventricular leukomalacia (PVL) is a common neuroimaging feature in individuals with spastic cerebral palsy. Difference in microscopic alterations in grey matter (GM) between premature and full-term children with PVL is still unclear.
- To investigate the impact of ischemic and hypoxic events on microstructure through analyzing GM changes in cerebral palsy patients with PVL, including premature PVL (pPVL) and full-term PVL (fPVL).

Purpose and Methods



Results & Conclusion(s)

- Compared to the HC, there were reductions of total intracranial volume, GM, and white matter (WM) volume in the pPVL group, also reduced volume in bilateral thalamic; only reduced volume in the left thalamic volume within the fPVL group ($p < 0.001$).
- Correlation analysis showed a stronger association of thalamic volume changes with gross motor function scores in pPVL groups.

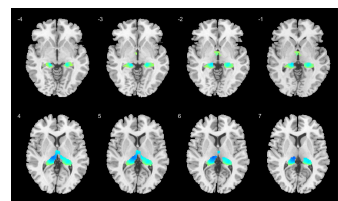


Fig 1. Comparison of GM volumes between the whole PVL group and HC group at a threshold of $P < 0.0001$ (FWE corrected).


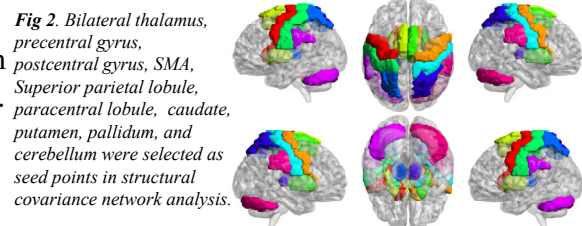


Fig 3. Structural correlation matrix of pPVL, HC and fPVL group according to the selected seed points in brain regions.

Table 1 Regions of significant volume differences between PVL and Healthy controls (HC > PVL)

| Anatomical Region | MNI coordinates | | | voxel | p-value FWE corrected |
|------------------------|-----------------|-----|----|-------|-----------------------|
| | X | Y | Z | | |
| <i>PVL versus HC</i> | | | | | |
| Left thalamus | -29 | -21 | 29 | 2460 | <.0001 |
| Right thalamus | 27 | -33 | 30 | 2298 | <.0001 |
| <i>pPVL versus HC</i> | | | | | |
| Left thalamus | -14 | -21 | 9 | 2446 | <.0001 |
| Right thalamus | 17 | -23 | 15 | 2342 | <.0001 |
| <i>fPVL versus HC</i> | | | | | |
| Left thalamus | -9 | -21 | 11 | 2044 | <.0001 |
| Left Lentiform Nucleus | -20 | -4 | 7 | 172 | <.0001 |

Cluster threshold set at 100 voxels using $p < .0001$; Brain regions are based on AAL atlas. FWE, family wise error; MNI, Montreal Neurological Institute

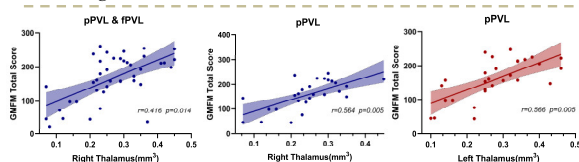


Fig 4. Correlation between GM volume and motor scores in PVL and PVL subtypes

- Compared with the HC group, the structural association of gray matter volume between right thalamus and right posterior central gyrus increased in pPVL group, and the structural association between thalamus and cerebellar hemisphere increased in fPVL group.
- Compared with the fPVL group, the structural association between right thalamus-cerebellar hemisphere in pPVL group tends to decrease.

Conclusions: Preterm and full-term PVL children have different thalamic volume changes, as well as abnormalities in the structural covariance network associated with the thalamus.