



Paper no: 20

**Predicting response to initial chemotherapy in pediatric lymphoma using a semi quantitative CECT-based abdomino-thoracic score:
*a pilot prospective observational study.***



Ishan Kumar, MBBS, MD, DNB
Department of Radiodiagnosis and Imaging,
Institute of Medical Sciences, Banaras Hindu University, Varanasi, India



Co-authors: Shashank Sonkar, Priyanka Aggarwal, Vineeta Gupta, Ram Chandra Shukla, Ashish Verma

Background

Pediatric Lymphoma: third most common malignancy of childhood

Imaging modalities: US, Contrast Enhanced CT, FDG-PET, PET-CT, Whole body MRI

CT scan has become the standard of care in pre-treatment staging

Do not emphasize the estimation of lymph nodal disease burden based on the anatomical extent of the nodal involvement

Purpose

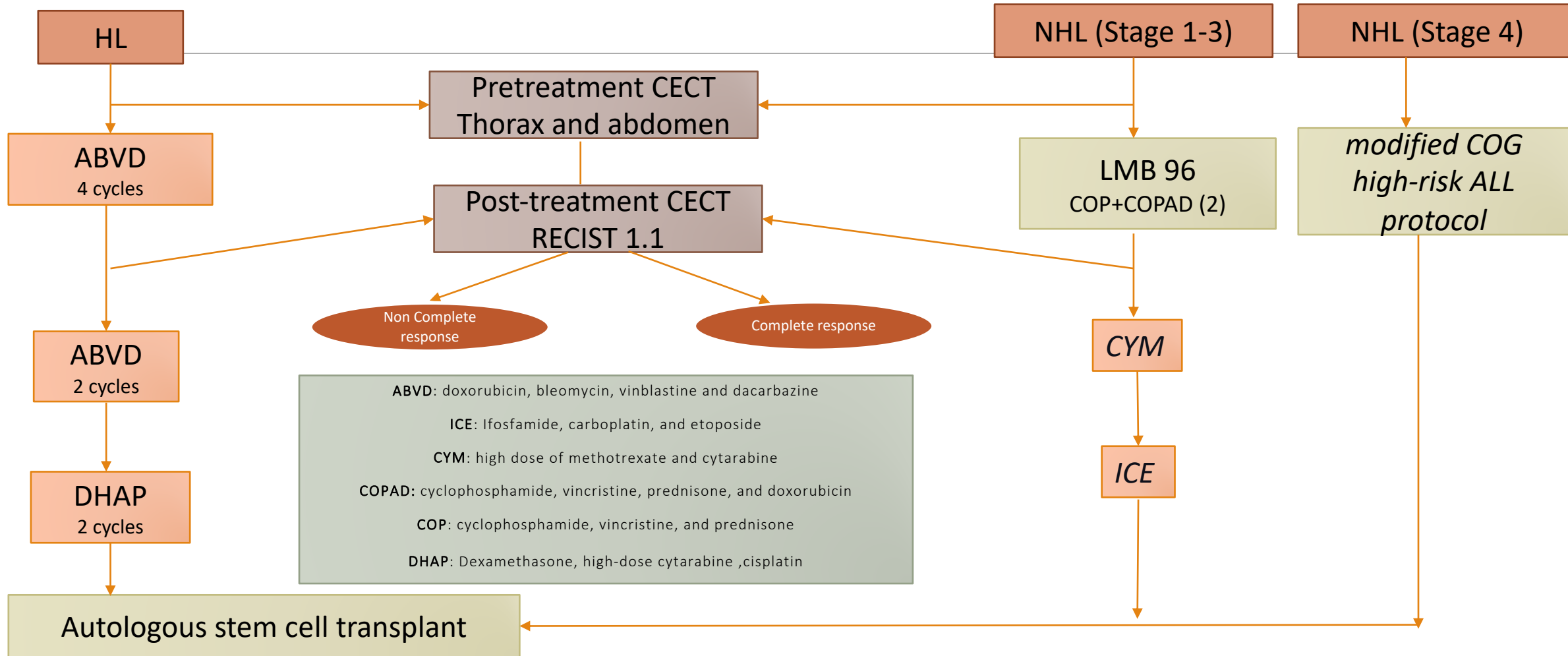
To validate a **semiquantitative lymph nodal scoring system** based on the anatomical pattern of involvement to

- Systematically estimate the **burden** of thoraco-abdominal lymph nodal disease in childhood lymphoma
- to **predict response** to the primary therapy
- to distinguish **HL and NHL**

Methods

prospective observational study

Children (<18 years of age) with a histopathological diagnosis of lymphoma



Combined score (total score 20): Thoracic score + Abdominal score

THORACIC SCORE (SCORE 10)

- Superior mediastinal
- Paratracheal
- Subaortic
- Paraaortic
- Subcarinal
- Para esophageal
- Pulmonary ligament
- Hilar
- Interlobar
- Chest wall & axillary LN

ABDOMINAL SCORE (SCORE 10)

- Abdominal wall LN
- Diaphragmatic LN
- Liver
- Stomach
- Pancreatic LN
- Mesenteric LN
- Colon LN
- Suprarenal retroperitoneal LN
- Infrarenal retroperitoneal LN
- Pelvic LN

Region	LN stations
Abdominal wall LN	<i>Anterior</i> Superficial: supraumbilical LN/infraumbilical LN Deep: superior epigastric pathway/inferior epigastric pathway/intercostal pathway <i>Posterior</i> Superficial: LN along superficial circumflex vessels Deep: LN along lumbar arteries/LN along deep circumflex iliac artery
Diaphragmatic LN	Anterior diaphragmatic LN/middle diaphragmatic LN/retrocrural LN/inferior diaphragmatic LN
Liver	Cystic duct LN/gastrohepatic/hepaticoduodenal LN/falciform ligament LN/falciform ligament/deep superior epigastric LN (subxiphoid)
Stomach	At lesser curvature: right paracardial LN/lesser curvature LN/suprapyloric nodes At greater curvature: left paracardial/proximal left greater curvature LN/distal left greater curvature LN/right greater curvature LN/infrapyloric LN Near lesser curvature: left gastric artery LN/common hepatic artery LN/cealic trunk LN/left hepatoduodenal ligament LN/posterior hepatoduodenal ligament LN/foramen of Winslow LN
Pancreas	Pancreaticoduodenal LN: anterior/posterior/inferior Dorsal pathway posterior to pancreatic head: superior/ inferior Body/tail: along proximal splenic artery/along distal splenic artery/splenic hilar LN
Mesenteric LN (small bowel)	Juxtaintestinal LN/intermediate mesenteric nodes/central mesenteric LN
Colon	Cecum: periappendiceal/ anterior cecal/ posterior cecal Colon: epicolic LN/ paracolic LN/intermediate mesocolic/terminal colic LN • Intermediate mesocolic LN: ileocolic LN/right colic LN/middle colic LN/left ascending and descending colic LN/ left colic LN/LN along sigmoidal artery • Terminal colic LN: SMA/IMA/middle colic Perirectal LN: sigmoid mesocolon LN/mesorectal LN Perianal LN: above pectinate line/below pectinate line
Retroperitoneal	Retrocaval LN/ precaval LN/laterocaval LN/aorticaval LN/preaortic LN/retroaortic LN/lateral aortic LN • Level: aortic hiatus LN/ middle paraaortic/ caudal paraaortic Perirenal: renal hilar/suprahilar/posterosuperior perirenal LN/posteroinferior perirenal LN
Pelvic	Common iliac LN: lateral/medial/middle External iliac LN: lateral/middle/obturator Internal iliac LN: junctional/ anterior/iliac circumflex/lateral circumflex Perivisceral: • perivesical: prevesical/postvesical/lateral vesical • periuterine/parametrial/pericervical LN • periprostatic/ periseminal vesicle LN Others: posterior iliac crest LN/ gonadal vessels LN Inguinal LN: superficial/ deep inguinal LN

Regional abdominal pattern scores

Gastric nodal score : total score 9

Celiac axis -peripancreatic : total score 13

Mesentrico-colic score: total score 14

Retroperitoneal score : Total score 17

Kumar et al.

Indian J Radiol Imaging. 2022;32(1):62-70.

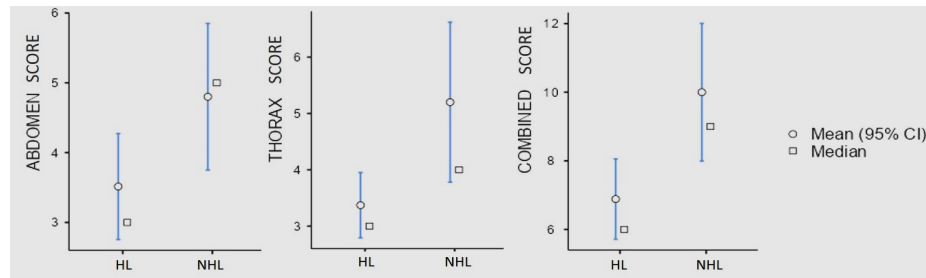
Results

Fifty patients : Mean age of 7.56 ± 3.01 years (M: F= 39:11).

- Hodgkin lymphoma (HL) : 35
- Non Hodgkin lymphoma (NHL) : 15

Comparison between HL and NHL

Lymph nodes/ nodal score	HL	NHL	p-value
Abdominal score	3.5±2.3	4.8±2.1	0.035
Thoracic score	3.3±1.75	5.2±2.8	0.026
Combined score	6.89±3.54	10.0±3.96	0.01



Thorax			
Upper paratracheal	5 (14%)	6 (40%)	0.44
Lower paratracheal	7 (20%)	8 (53%)	0.018
Pulmonary ligament	4 (11.4%)	7 (47%)	0.006

Lymph nodes/ nodal score	HL	NHL	p-value
Mesenteric			
Juxta-intestinal	18 (51%)	13 (87%)	0.019
Intermediate	18 (51%)	13 (87%)	0.019
Central	17(51.4%)	12 (80%)	0.039
Retroperitoneal			
Latrocaval	18 (51%)	13 (87%)	0.019
Aortocaval	19 (54%)	14 (93%)	0.008
Preaortic	19 (54%)	14 (93%)	0.008
Retroaortic	20 (57%)	14 (93%)	0.012
Lateral aortic	21 (60%)	14 (93%)	0.018
Aortic hiatus	21 (60%)	14 (93%)	0.018
Middle paraaortic	20 (57%)	14 (93%)	0.012
Caudal paraaortic	19 (54%)	14 (93%)	0.008
Renal hilar	20 (57%)	13 (87%)	0.043
Suprahilar	17(51.4%)	13 (87%)	0.012
Posterosuperior perirenal	16 (46%)	13 (87%)	0.007
Posteroinferior perirenal	16 (46%)	12 (80%)	0.025
Retroperitoneal score (total 17)	7.51±5.92	12.4±3.89	0.005

Response assessment in HL and NHL

Lymph nodes/score	Complete response	Non complete response	P value
Hodgkin Lymphoma			
HL (n=35)	23(65.7%)	12 (34.3%)	
Mean abdominal score	2.48±1.56	5.50±2.20	<0.001
Mean thorax score	2.78 ± 1.31	4.50 ± 1.98	0.016
Combined score	5.26 ±2.09	10.00± 3.72	<0.001
Regional abdominal scores			
Celiac axis-pancreatic	0.95 ±1.6	4.92± 4.29	<0.001
Retroperitoneal score	6.27± 6.017	9.25 ± 5.38	0.163
Mesentrico-colic score	4.50 ± 5.6	11.42 ± 4.87	0.001
Gastric score	0.046 ± 0.21	1.58 ± 3.03	0.022
Non-Hodgkin Lymphoma			
NHL (n=15)	6 (40%)	9 (60%)	
Mean abdominal score	3.67 ± 0.52	5.56± 2.40	0.012
Mean thorax score	2.67 ±0.82	6.89 ± 2.32	<0.001
Combined score	6.33 ± 0.82	12.44 ±3.21	<0.001

Children with complete response in both HL and NHL group showed a lower thoracic, abdominal, and combined scores than those who did not show complete response to primary treatment.

Discussion

This study is the first one to elaborate on the differences in the nodal pattern of involvement between HL and NHL

Points favoring NHL

- **Higher nodal burden** : higher thoracic, abdominal and combined scores
- Higher involvement of **retroperitoneal and mesenteric** lymph nodes
 - Increased incidence of IVC compression
- Higher incidence of enlarged **upper and lower paratracheal**, and pulmonary ligament LN
 - Increased Airway compression

Study	Modality	Lymph nodal staging system	Reference
Cotswolds modifications of the Ann Arbor staging (Hodgkin lymphoma)	CT	4 stages: <ul style="list-style-type: none"> • single LN, • ≥ 2 LN ipsilateral to diaphragm, • LN on both sides of the diaphragm a • diffuse disease with 1 extralymphatic organ bulky disease: > 10 cm or $\geq 1/3^{\text{rd}}$ of transverse thoracic diameter on Chest X ray -PA view.	J Clin Oncol. 1989;7: 1630-1636.
International Pediatric Non-Hodgkin Lymphoma Staging System (IPNHLSS)	CT	4 stages <ul style="list-style-type: none"> • Single LN (exclusion of abdomen/chest) • ≥ 2 LN ipsilateral to diaphragm • ≥ 2 LN both sides of diaphragm/ chest involvement • CNS/ bone marrow involvement 	J Clin Oncol. 2015;33(18):2112-2118.
La Fougere et al, 2006	PET-CT	7 regions: cervical, thoracic, abdominal , pelvic, bone marrow, extra-nodular and spleen.	Eur J Nucl Med Mol Imaging. 2006;33:1417-1425
Freudenberg et al, 2004	PET-CT	11 regions: cervical, supraclavicular, paratracheal, mediastinal, hilar, axillary, coeliac, para-aortic, mesenteric, iliac and inguinal Four anatomical groups: (1) head and neck, (2) chest, (3) abdomen and (4) pelvis.	Eur J Nucl Med Mol Imaging. 2004;31:325-329
EuroNet-PHL	CT or MRI	Bulky disease: Volume measurements of the contiguous mediastinal Adenopathy >200 mL <ul style="list-style-type: none"> • software-based volumetry • multiplanar volume reconstruction : $(Ax \times B \times C) \div 2$ 	Pediatr Radiol. 2019;49(11):1545-1564
Brennan et al	CT WB-MRI	Thorax (8 regions): anterior mediastinum, right paratracheal, right tracheobronchial, left paratracheal, left tracheobronchial, aortopulmonary window, subcarinal, and epicardial regions Abdomen (5 regions) : Paraaortic, mesenteric, iliac and pelvic sidewall, inguinal, visceral	Am J Roentgenol. 2005;185(3):711-716.
Sabri et al	MRI	Thorax (10 regions): Paratracheal, Prevascular, Paraaortic, Subaortic, Hilar, Sub carinal, Para esophageal, Cardiophrenic, Internal mammary, Supra clavicular	Egypt J Radiol Nucl Med 2021; 52: 215
Present study	CT	Thorax (10 regions) Abdomen (10 regions)	

Conclusions

Semiquantitative scoring of lymph nodal distribution

- *A better estimate of extent of disease*
 - *offers both diagnostic and prognostic value*

Limitations

- *low number of included patients*
- *CT instead of PET-CT*
- *the non-inclusion of cervical lymph nodes*
- *Did not assess interobserver agreement*