

Applying the updated PRETEXT system in staging of hepatoblastoma in children: Key images to remember them



JISUN HWANG¹, M.D.

HEE MANG YOON², AH YOUNG JUNG², YOUNG AH CHO², JIN SEONG LEE²

¹ DEPARTMENT OF RADIOLOGY, DONGTAN SACRED HEART HOSPITAL, SOUTH KOREA

² DEPARTMENT OF RADIOLOGY, ASAN MEDICAL CENTER, SOUTH KOREA

- Learning objectives -

- To review the definitions of PRETEXT groups and annotation factors in 2017 PRETEXT system for pediatric hepatoblastoma
- To review typical CT and MRI images of PRETEXT groups and annotation factors
- To learn confusing scenarios for staging hepatoblastoma by sample cases

- OVERVIEW -

Introduction

- Clinical importance of PRETEXT system
- The background of updates to the PRETEXT system

PRETEXT groups

- Definitions and sample cases with positive findings

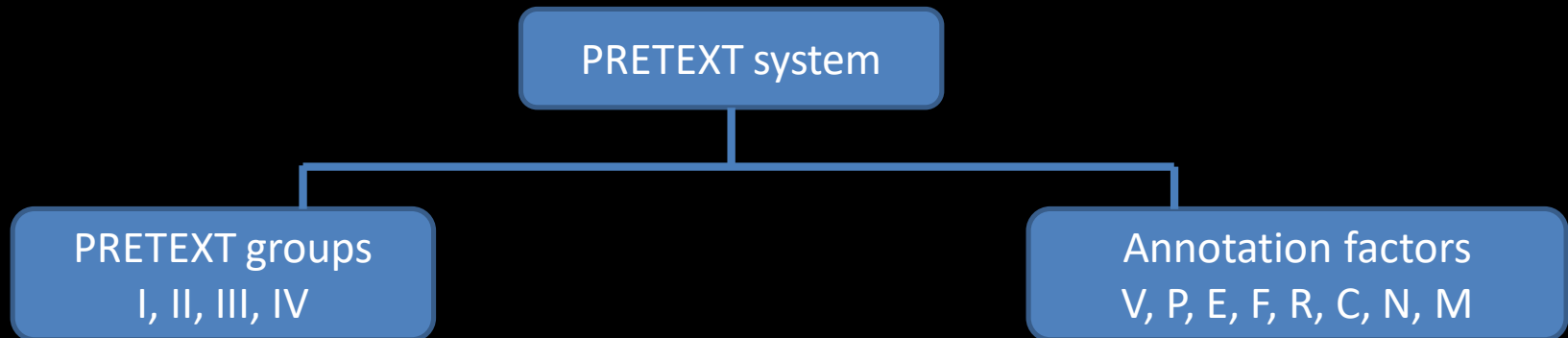
Annotation factors (V,P,E,F,R,C,N,M)

- Definitions and sample cases with positive findings

The background of updates to the PRETEXT system



- PRETEXT system is used to describe tumor extent before any therapy and stratify risk for treatment planning.



- After SIOPEL (the International Childhood Liver Tumor Strategy Group) first described the original PRETEXT system in 1990, disparate definitions and staging systems have been used by multicenter trial groups.
 - SIOPEL, the German Society for Pediatric Oncology and Hematology, and the Japanese Study Group for Pediatric Liver Tumors
- The **updated 2017 PRETEXT system** aimed to clarify and unite definitions for its use in future collaborative trial (*Pediatric Radiology* (2018) 48:536–554).

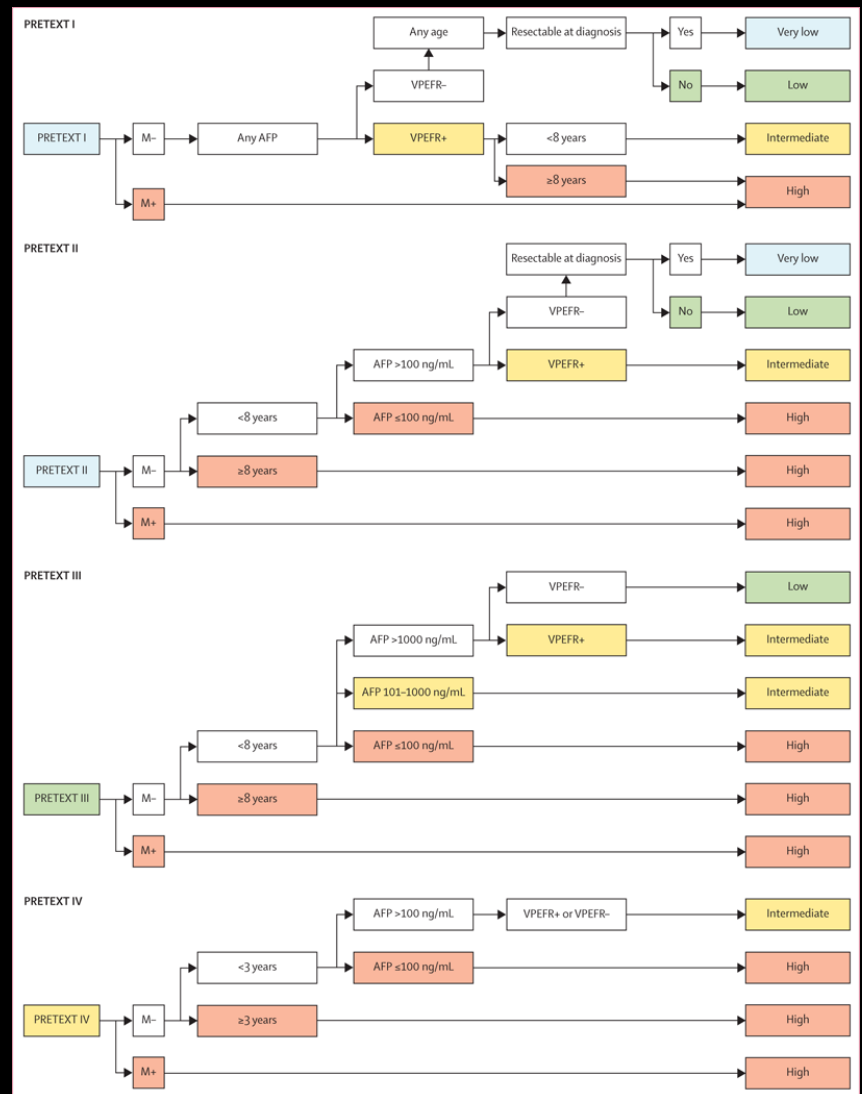
The clinical importance of the PRETEXT system



- Many studies have found **poor prognostic factors** such as low AFP level , **advanced PRETEXT group, and distant metastases**.
 - (*Journal of clinical oncology* 2005, 23, 1245-1252)(*Pediatric blood & cancer* 2009, 53, 1016-1022) (*European journal of cancer* 2012, 48, 1543-1549) (*Cancer* 2002, 95, 172-182)
- The **2017 PRETEXT** is part of the **new international Hepatoblastoma Stratification system** developed by the Children's Hepatic tumors International Collaboration consortium (**CHIC-HS**).



- The CHIC consortium have created **CHIC-HS**, a risk stratification tree model, from the largest dataset assembled from prior multicenter trial groups.
- All the **clinical and imaging variables** used in CHIC-HS were found to be **associated with patient outcome**.
 - Age (≤ 2 , 3-7, ≥ 8), serum AFP (<100 , 100-999, 1000- 10^6 , $> 10^6$)
 - PRETEXT groups, all annotation factors except C and N
 - C and N were not evaluated



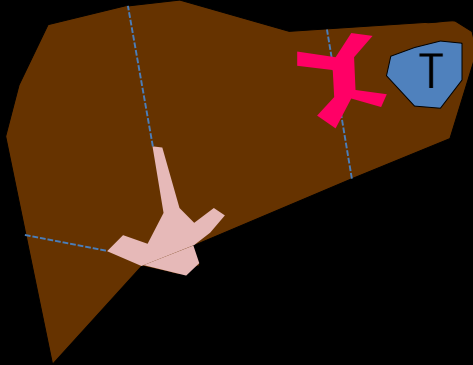


- The PRETEXT group (I, II, III or IV) is based on determining the **number of contiguous tumor-free liver sections**
- **Advanced PRETEXT group** is one of the traditional **poor prognostic factors** in hepatoblastoma
 - - (*Journal of clinical oncology* 2005, 23, 1245-1252)(*Pediatric blood & cancer* 2009, 53, 1016-1022)

PRETEXT groups

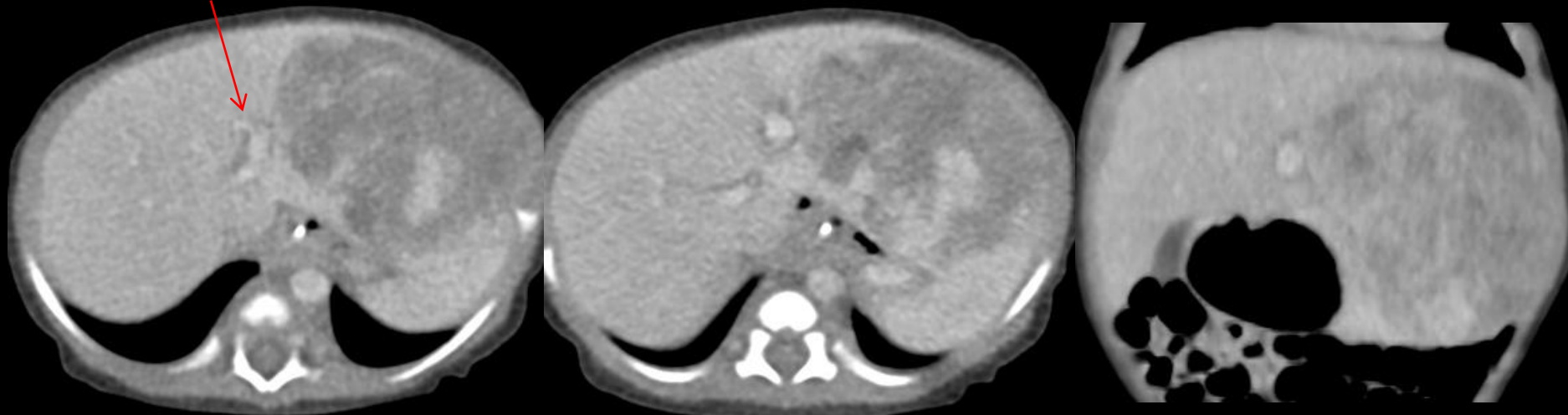

- **PRETEXT group 1**



- Uncommon and are typically small
- Three contiguous hepatic sections must be free of tumor. Therefore, PRETEXT I tumors can only involve either the left lateral or right posterior section

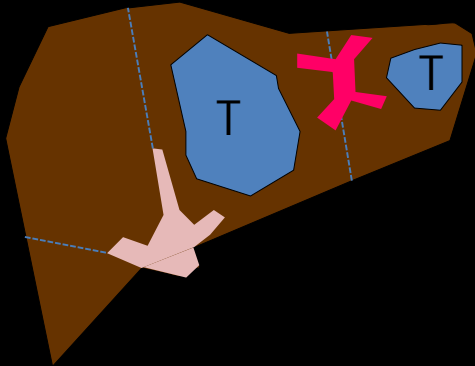
Umbilical portion of left PV



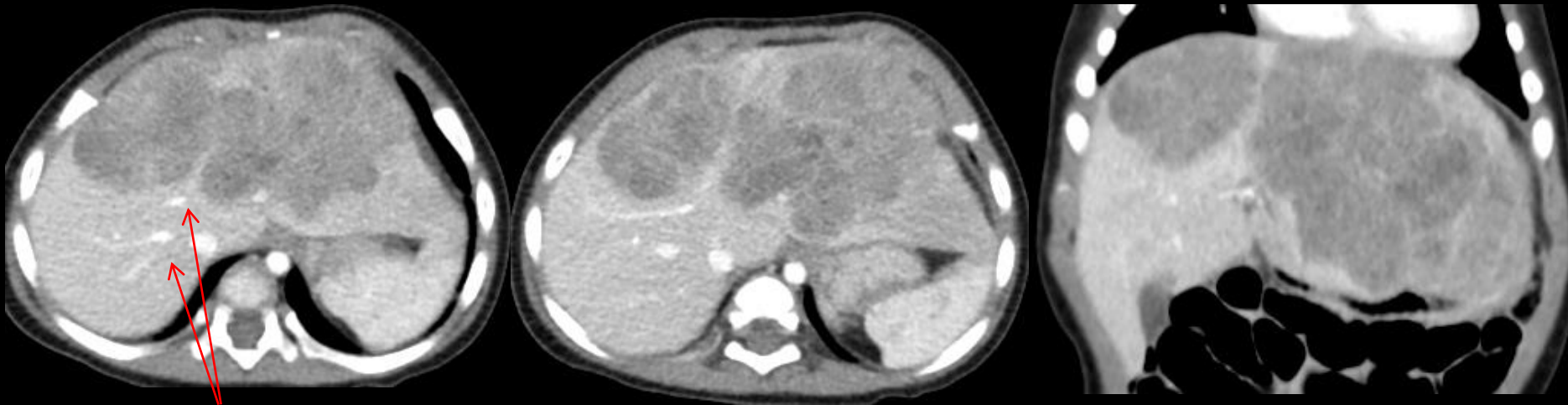
6months/M. A heterogeneous enhancing mass involving only left lateral segment of liver. Right lobe, left medial segment, and caudate lobe are free from tumor.



• PRETEXT group 2



- Two contiguous hepatic sections must be free of tumor
- Limited either to the right lobe or the left lobe of the liver
- They can involve either one or two sections of the liver



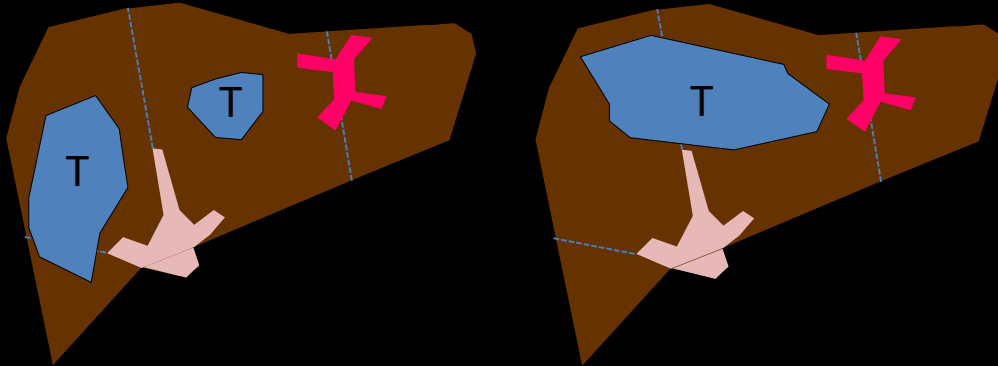
Right and middle HV

6months/F. A heterogeneous enhancing mass involving left medial and lateral segment of liver. Two contiguous hepatic sections are free from tumor.

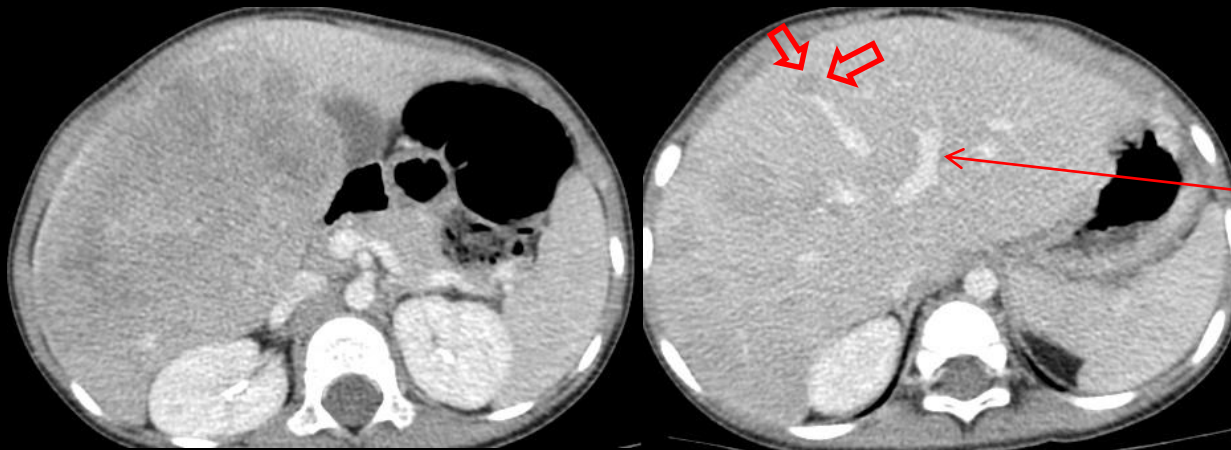
PRETEXT groups



- **PRETEXT group3**



- One hepatic section must be free of tumor
- Central tumors that involve only the left medial and right anterior sections result in only one contiguous tumor-free section and are considered PRETEXT III

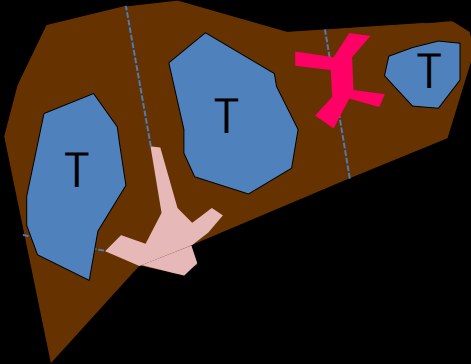


Umbilical portion of left PV

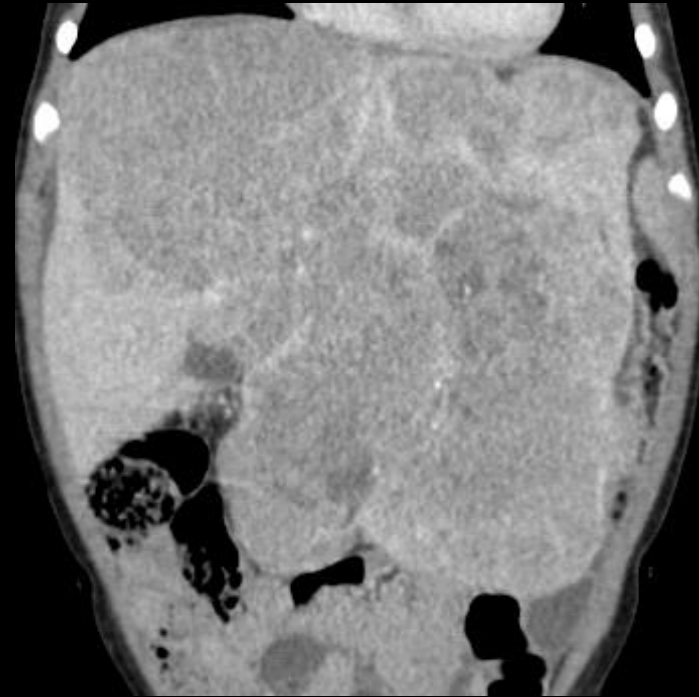
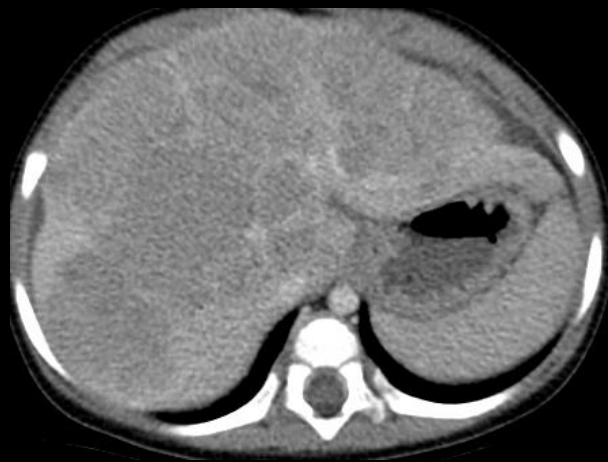2/M. Multiple heterogeneous enhancing masses involving right anterior and posterior sections of liver. A small daughter nodule (arrow) is seen just medial to middle hepatic vein. Therefore, only one hepatic section is free from tumor.



- **PRETEXT group 4**



- Tumor affects all four hepatic sections
- Almost always multifocal or infiltrative tumor



1/F. A lobulating enhancing masses involving all four hepatic sections. Mass shows punctate calcifications and necrotic areas.

Part II. Annotation factors



	Annotation factors
V	Hepatic venous/IVC involvement
P	Portal venous involvement
E	Extrahepatic tumor extension
F	Multifocality
R	Tumor rupture
C	Caudate lobe
N	Lymph node metastasis
M	Distant metastasis

Hepatic venous/IVC involvement (V)



- Difference between the definitions used in the most recent SIOPEL and COG trials centers on the definitions of various degrees of vascular involvement

	SIOPEL	COG
Vascular Involvement	Completely obstructed or circumferentially encased, or findings of tumor invasion	Within 1 cm of the vessel, abutted or compressed vessels were also said to have some degree of vascular involvement
V-status	V1,V2,V3 → Number of obstructed, encased or invaded veins	Positive = If all three HV or IVC met one of the following criteria V0 – tumor within 1 cm of vessel V1 – tumor abutting vessel V2 – tumor compressing vessel V3 – intravascular tumor thrombus

Hepatic venous/IVC involvement (V)

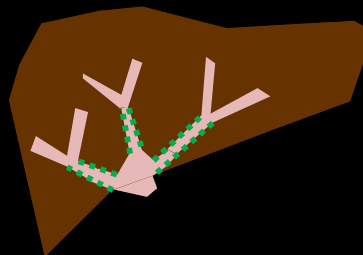


- To address these differences, a consensus definition was created that includes information from both the SIOPEL and COG approaches

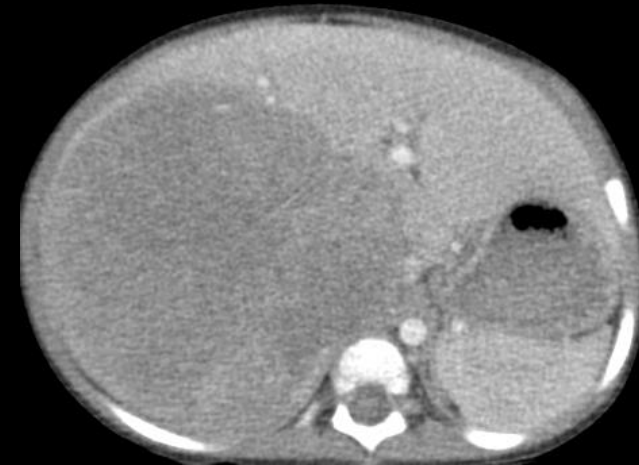
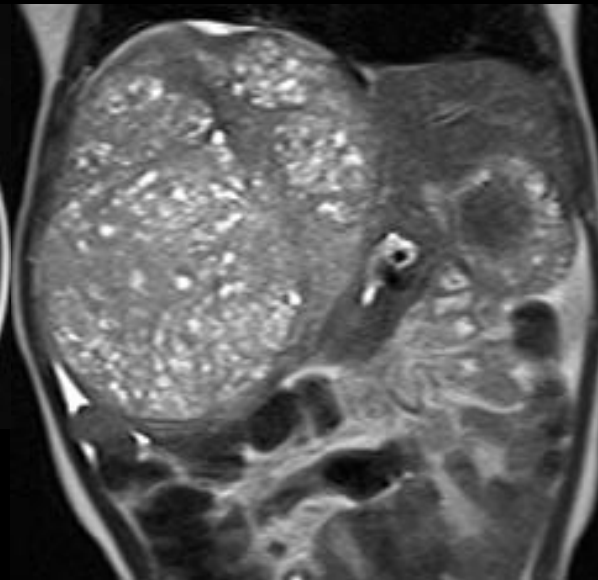
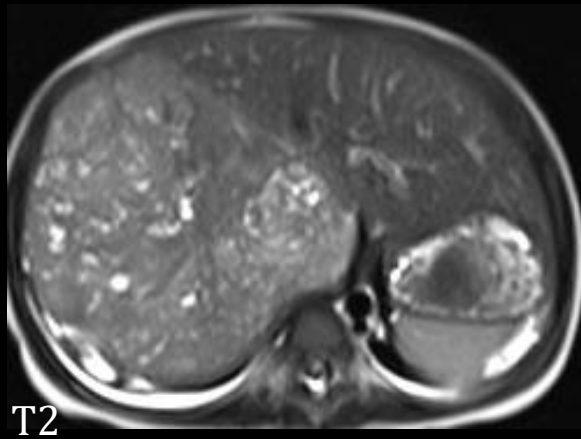
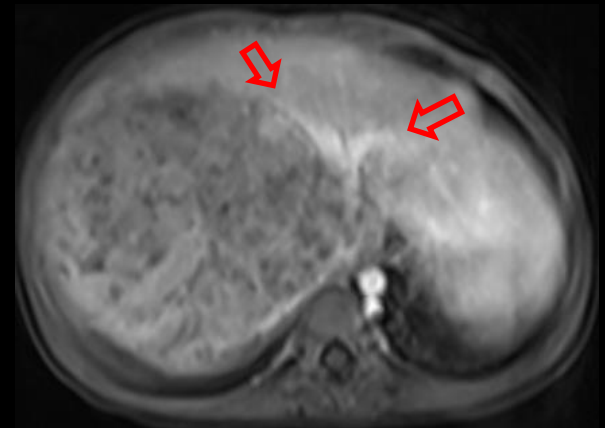
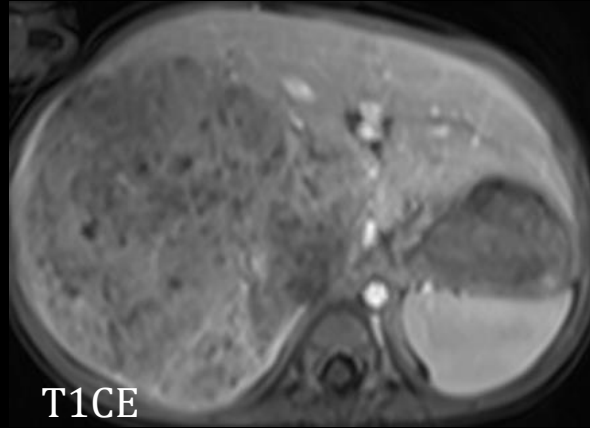
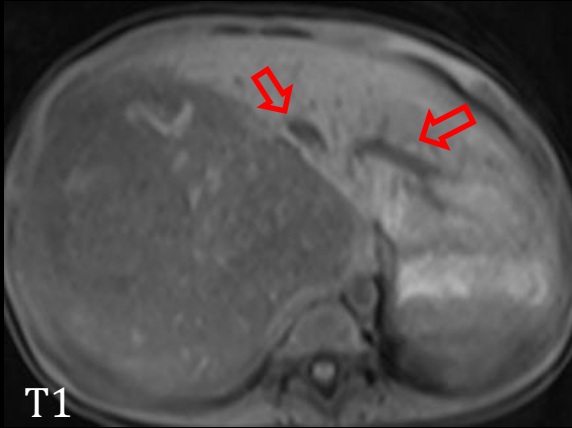
→ V-status: either V-negative or V-positive

~~V1, V2~~

- One of the following criteria : V (+)
 - Tumor obliterates or encases **all three HV** or the **intrahepatic IVC**
 - Tumor thrombus in **any HV** or the **intrahepatic IVC**
- Obliterates** mean that the lumen is no longer visible
- Encasement** by tumor means more than 50% or 180°
- “HV” definition**: between the confluence of the three HV at IVC and the most central major branch of HV

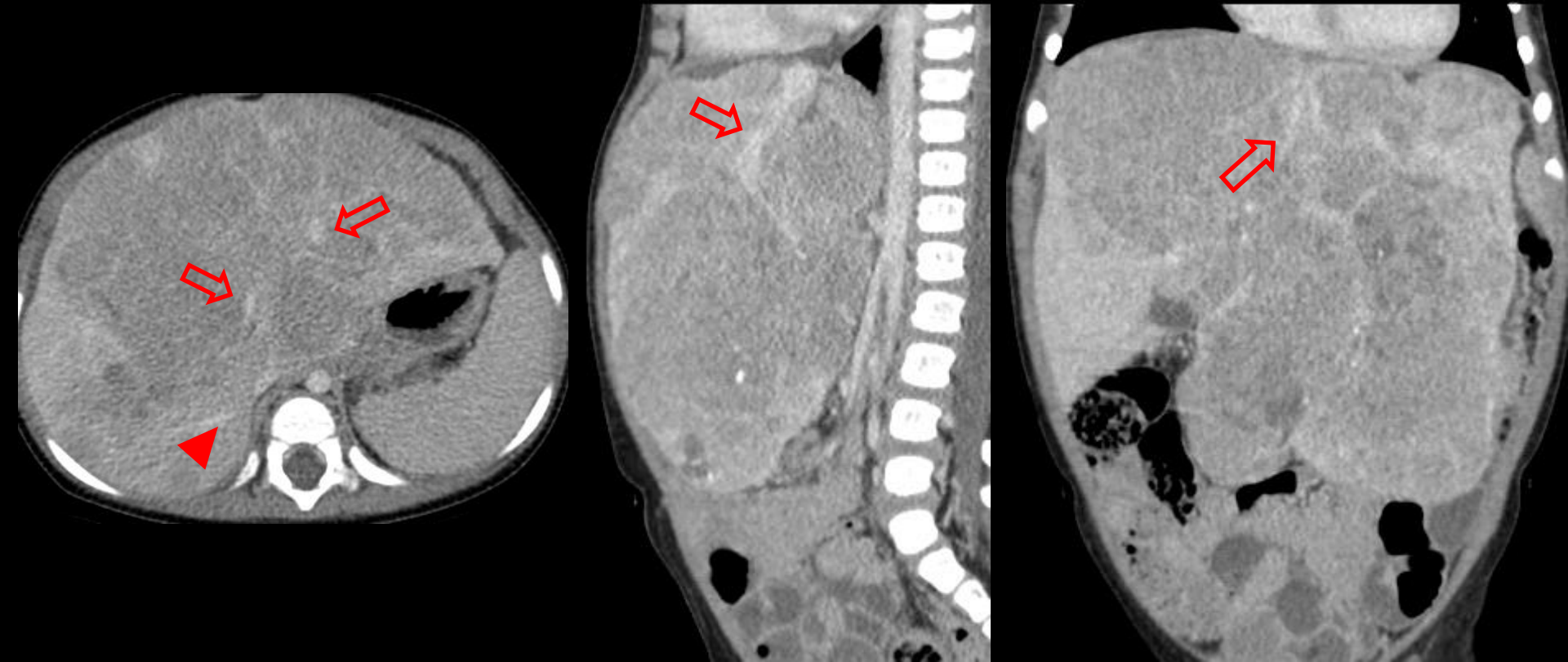


Right HV (only) obliteration → V(-)



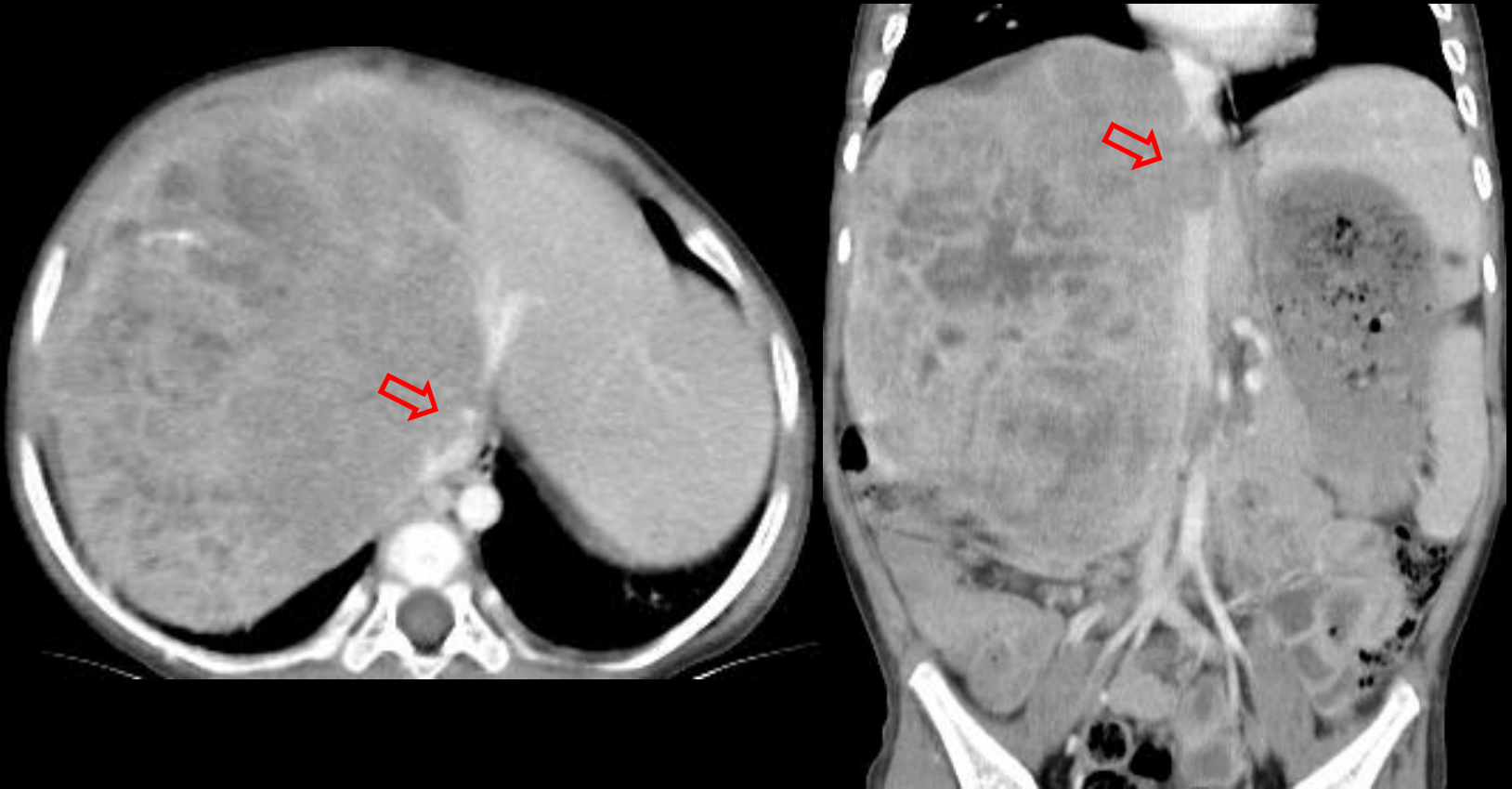
1/M. Large heterogeneous enhancing masses involving right anterior and posterior sections of liver (PRETEXT II). Right HV is obliterated due to tumor and not seen. Middle and left HV are intact (arrows). Tumor shows numerous necrotic portions. For V (+), all three hepatic veins must be obliterated.

Middle and left HV encasement → V(-)



1/F. PRETEXT IV. Tumor encases both middle and left HV (arrows). In this case, annotation factor V is considered as negative. Because right HV is free from tumor (arrowhead). **For V (+), all three hepatic veins must be involved.**

IVC thrombus → V(+)



1/M. PRETEXT II. Tumor thrombus (arrow) is seen in the lumen of intrahepatic IVC. Right HV is obliterated and middle HV is encased by tumor.

Portal venous involvement (P)



- Difference between the definitions used in the most recent SIOPEL and COG trials centers on the definitions of various degrees of vascular involvement

	SIOPEL	COG
Vascular Involvement	Completely obstructed or circumferentially encased, or findings of tumor invasion	Within 1 cm of the vessel, abutted or compressed vessels were also said to have some degree of vascular involvement
P-status	P1,P2 → Number of obstructed, encased or invaded veins	Positive = If both the right and left PV, or main PV met one of the following criteria P0 – tumor within 1 cm of vessel P1 – tumor abutting vessel P2 – tumor compressing vessel P3 – intravascular tumor thrombus

Portal venous involvement (P)

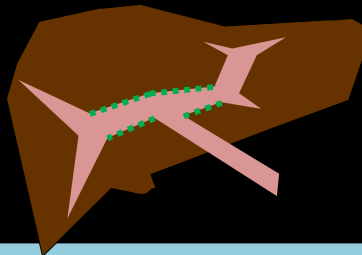


- P-status has been simplified in the new international collaborative 2017 PRETEXT definitions

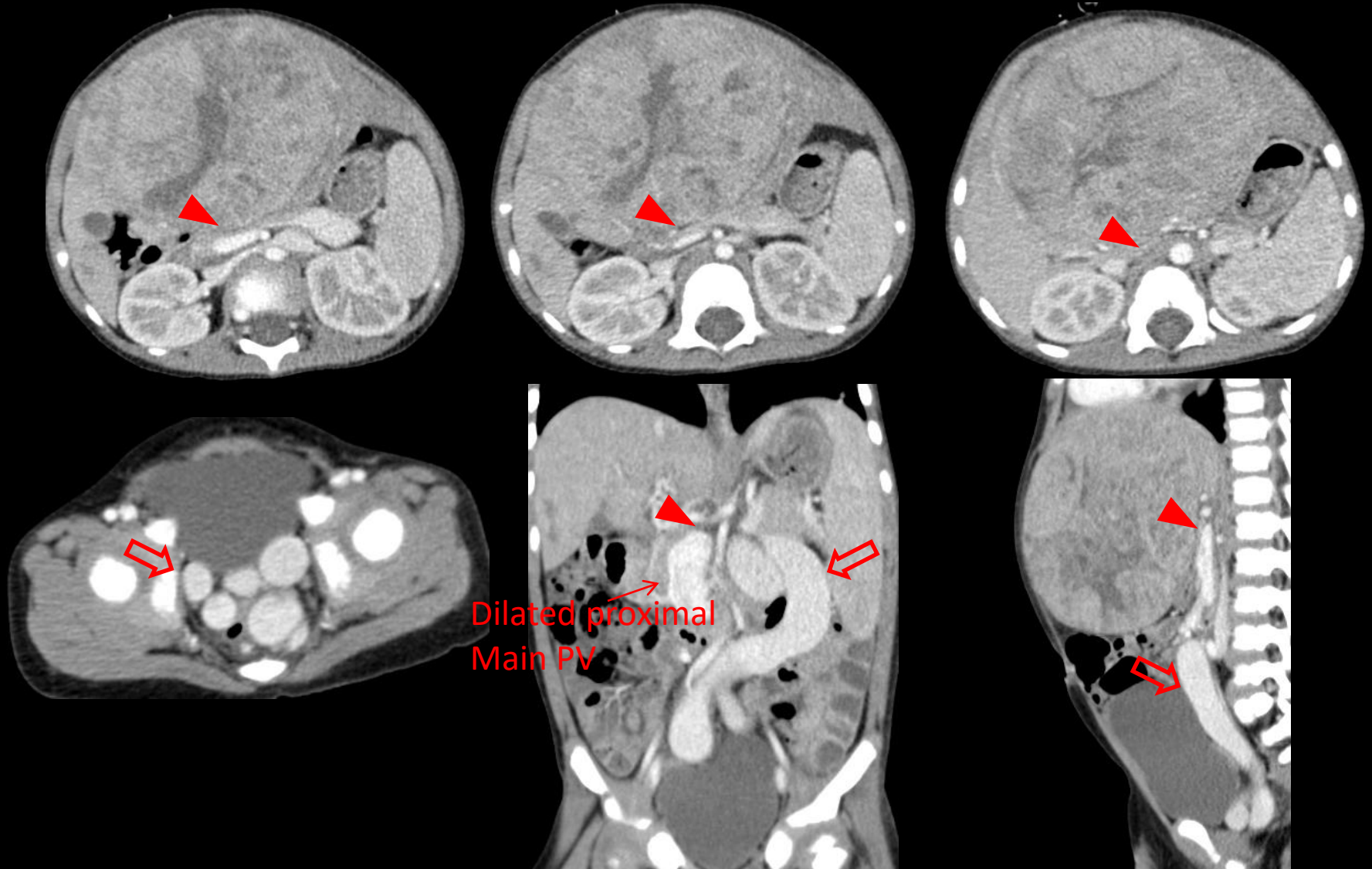
→ V-status: either P-negative or P-positive

~~P 1~~, ~~P 2~~

- One of the following criteria : P (+)
 1. Tumor obliterates or encases **either both PV** or the **main PV**
 2. Tumor thrombus in **either or both the right and left PV**
 3. Tumor thrombus in the **main PV**
- **Obliterates** mean that the lumen is no longer visible
- **Encasement** by tumor means more than 50% or 180°
- **“PV”** definition : extending from the bifurcation of the main PV to the first major branch of the vein

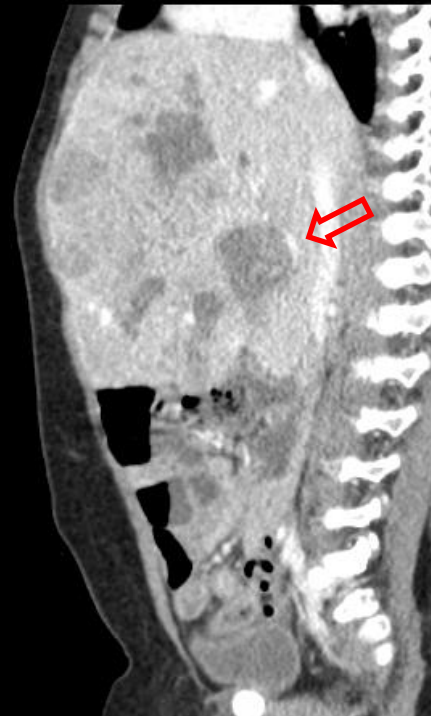
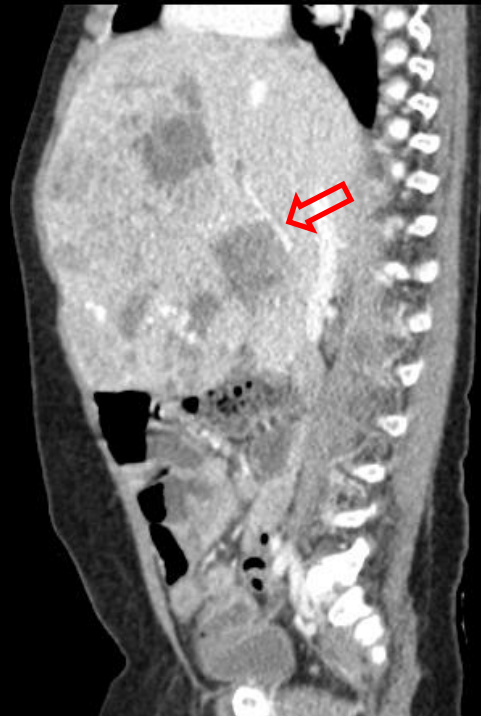
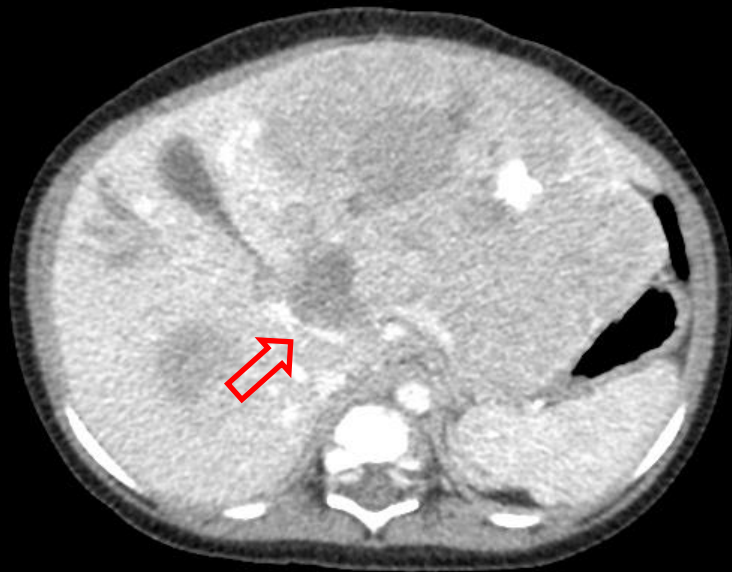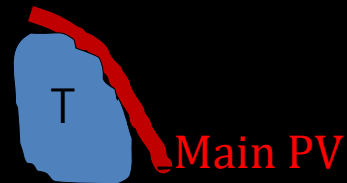Main PV obliteration → P (+)



3/M. PRETEXT III. Main PV is obliterated by tumor (arrowhead) and collateral veins are developed (arrow). Splenomegaly is present.

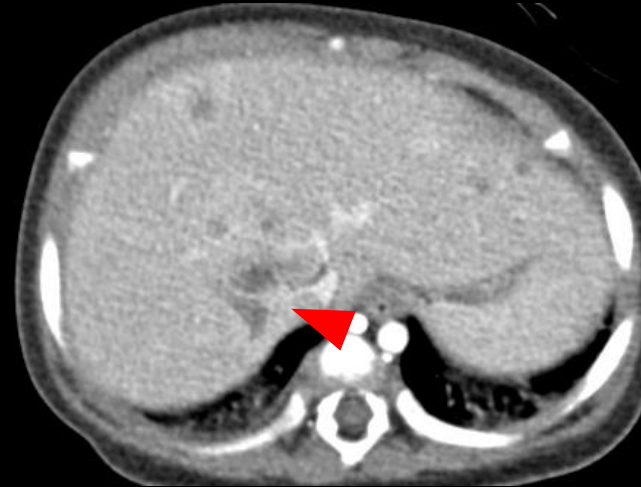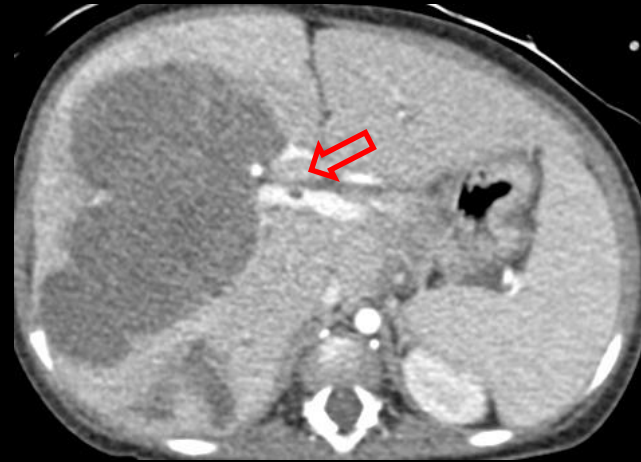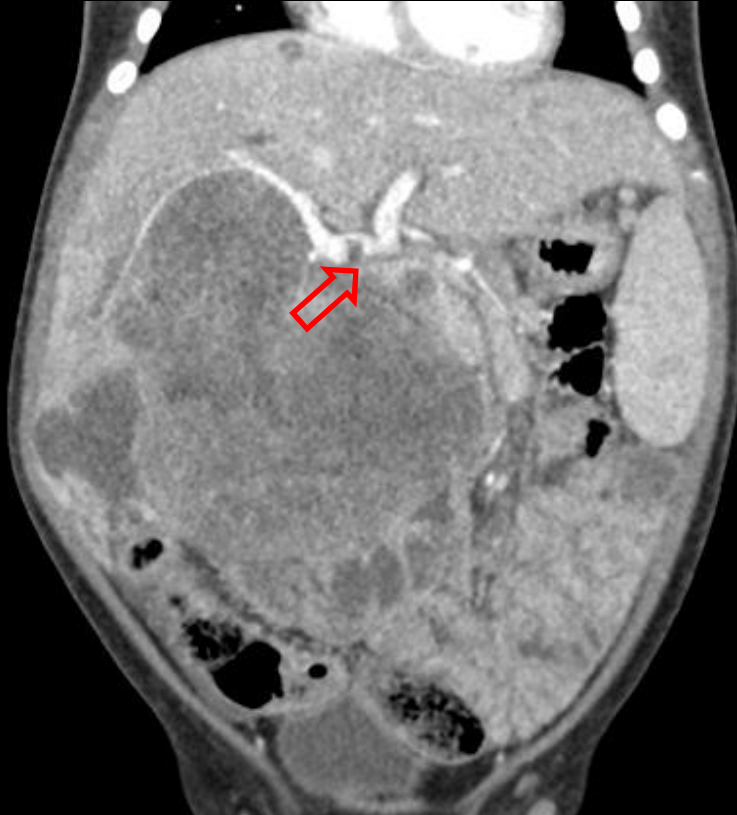Main PV encasement \rightarrow P (+)



1/M. PRETEXT IV.

Half of main PV is encased by tumor (arrow). Therefore, assignment of annotation factor P is positive.

Right PV thrombus → P (+)

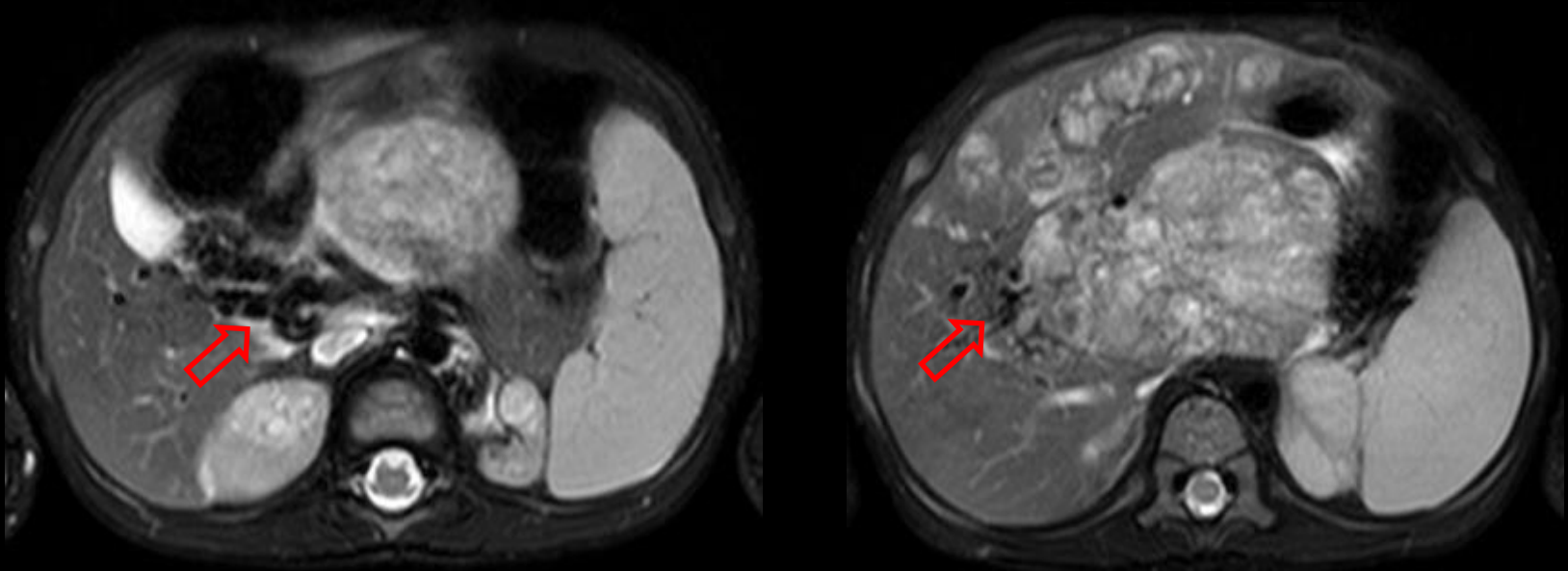


1/M. PRETEXT IV.

Thrombus in the right PV (arrow). Therefore, assignment of annotation factor P is positive. Right hepatic vein is encased by tumor (arrowhead). Tumor involves large area of right lobe and small daughter nodules are seen in the left lobe.

Cavernous transformation of main PV → P (+)

Cavernous transformation should be considered as evidence of tumor thrombus, according to 2017 PRETEXT



2/M. PRETEXT IV.

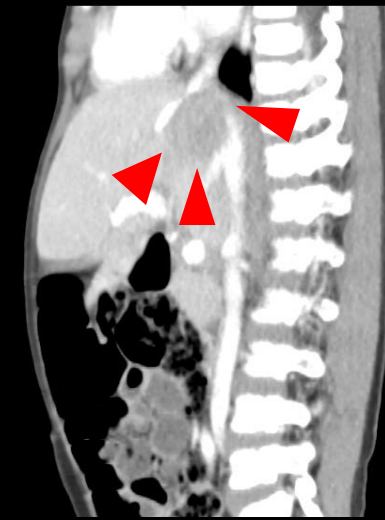
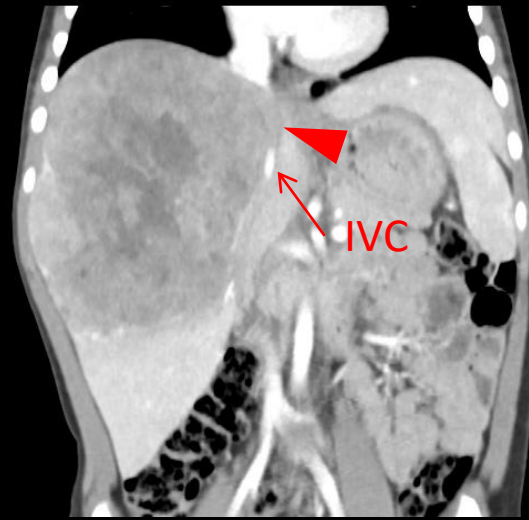
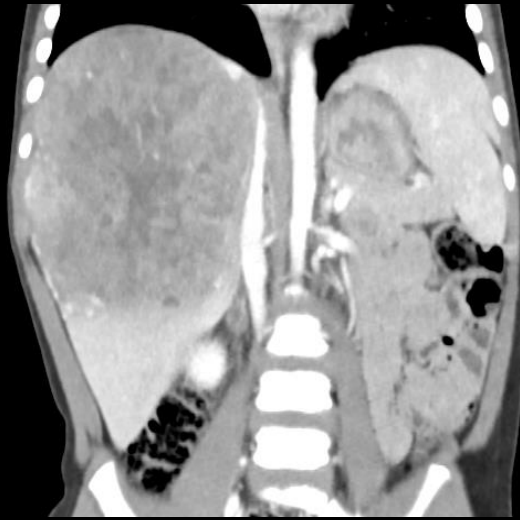
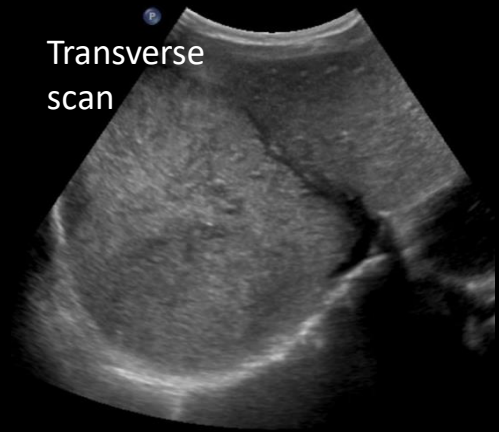
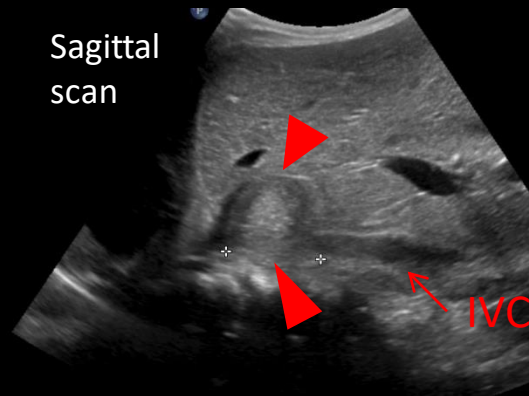
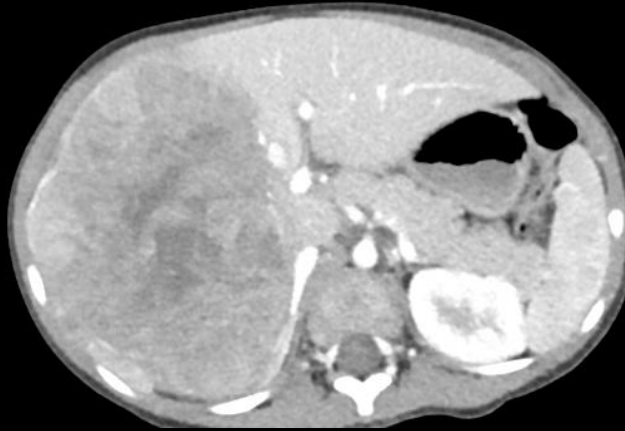MR images show signal void due to cavernous transformation (arrow) of the main PV. Portal vein thrombosis/tumor thrombus should be inferred. Dominant mass involves the caudate lobe and multifocal discrete tumors are noted in both hepatic lobes.

Extrahepatic tumor extension (E)



- One of the following criteria : E (+)
 1. Tumor crosses boundaries or tissue planes
 - Tumor is seen both above and below the diaphragm or extending through the abdominal wall
 2. Tumor is surrounded by normal tissue more than 180°
 3. Peritoneal nodules : one nodule $\geq 10\text{mm}$ or two or more nodules $\geq 5\text{mm}$
- Extrahepatic tumor extension is uncommon (5%)
- Most times, tumor is seen to be abutting and displacing nearby structures, not invading them
- Simple ascites is not considered extrahepatic disease

Diaphragm extension → E (+)

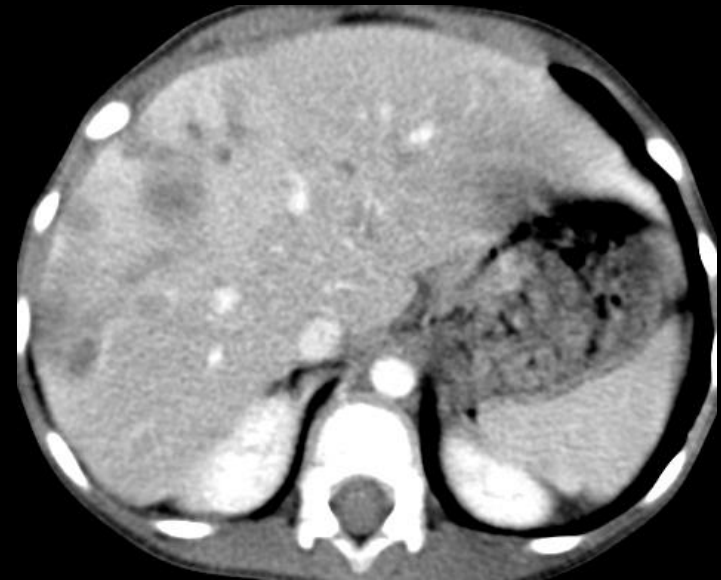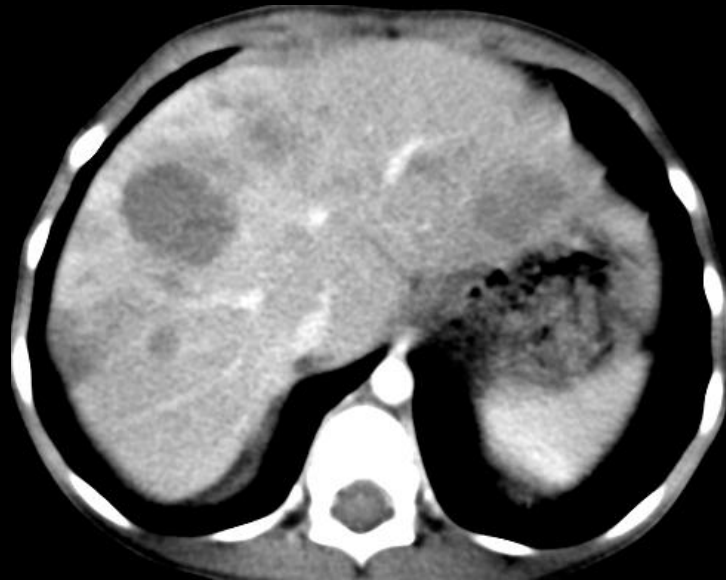


3/M. PRETEXT III (Tumor in S4 is not seen). Huge tumor in right hepatic lobe is surrounded by diaphragm more than 180°. Diagnosis of annotation factor E could be challenging, because frequently a large tumor is seen to abut the diaphragm, causing a loss of the plane between the affected structure and the tumor. However, in this case, diaphragmatic involvement is confirmed during operation. IVC obliteration (arrowhead) is seen by tumor.

Multifocality (F)



- Two or more separate hepatic tumors with normal liver tissue between the tumors
- Present in nearly 20% of patients with hepatoblastoma.
- Multiple studies have reported a **worse outcome** in patients with multifocal disease than those with a solitary focus of disease
(*European journal of cancer* 2000, 36, 1418-1425) (*European journal of cancer* 2012, 48, 1543-1549)



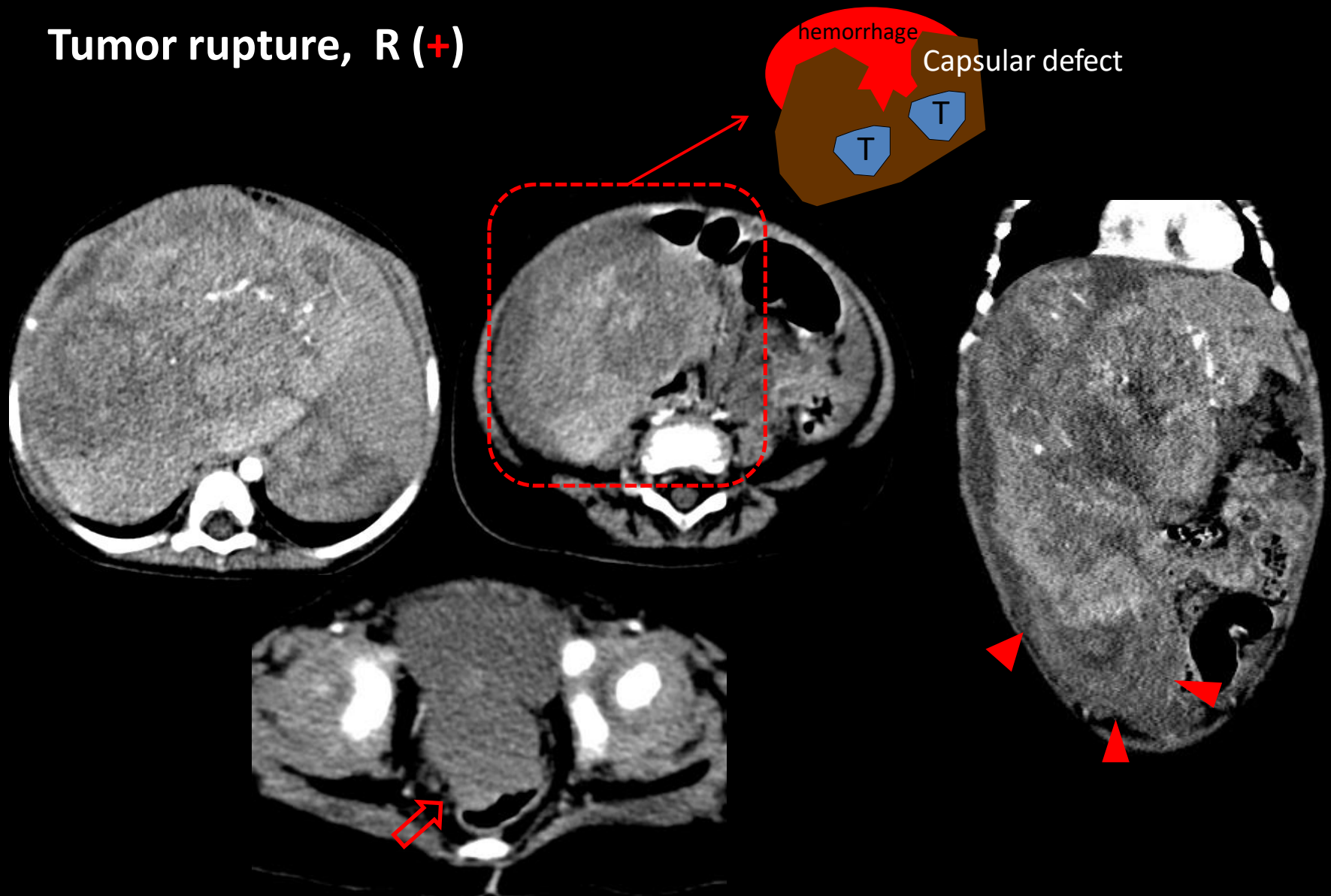
4/M. PRETEXT IV. Multifocal hepatic tumors (F)

Tumor rupture (R)



- Any findings of hemorrhage in the abdominal free fluid on imaging (US, CT, MRI)
- Visible rupture/hepatic capsular defect on imaging
- Pathologically diagnosed after paracentesis/up front resection

Tumor rupture, R (+)

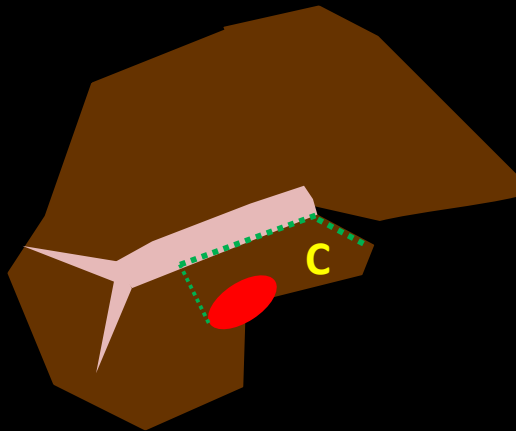


1/F. PRETEXT IV. CT taken at initial presentation shows large heterogeneous enhancing mass in both hepatic lobes. Focal capsular defect is seen in inferior aspect of S5 with surrounding hemoperitoneum (arrowhead). Free fluid of high density is demonstrated in cul-de-sac (arrow).

Caudate lobe (C)



- Involvement of the caudate lobe has implications for surgical planning
- The caudate lobe can be resected with either a right or a left hepatectomy, therefore, involvement of caudate lobe is considered at least PRETEXT II by definition

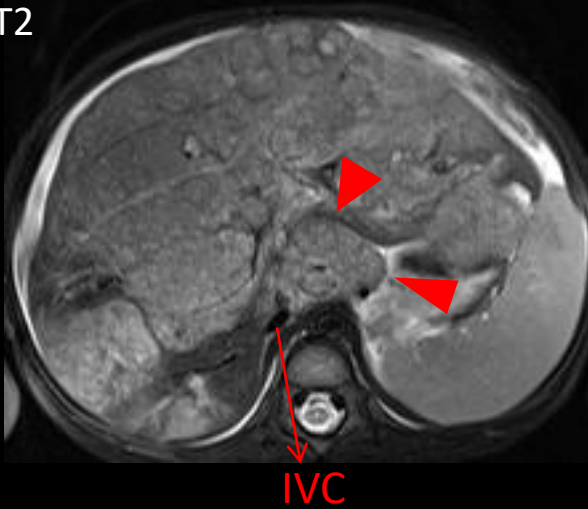


< Margins of caudate lobe >

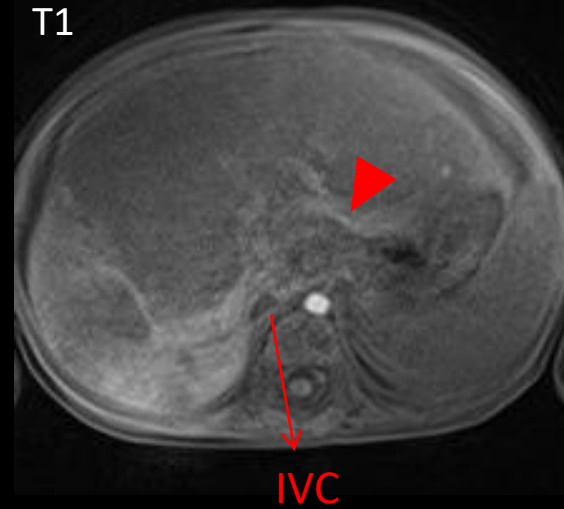
- Right : right lateral border of IVC
- Anterior : porta hepatis and ligamentum teres
- Left : ligamentum venosum
- Superior : liver dome
- Inferior : liver passes between main PV and IVC

Caudate lobe involvement → C (+)

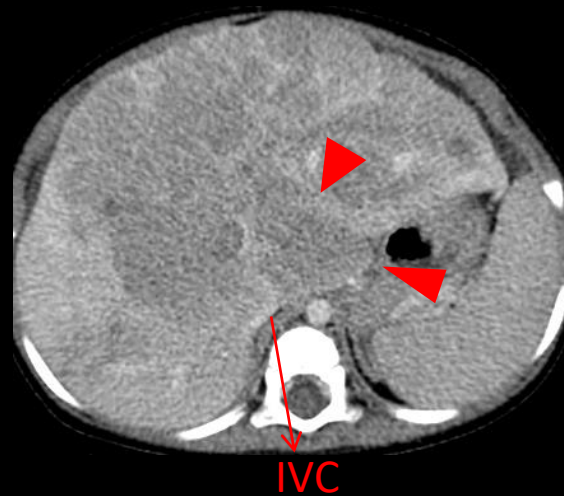
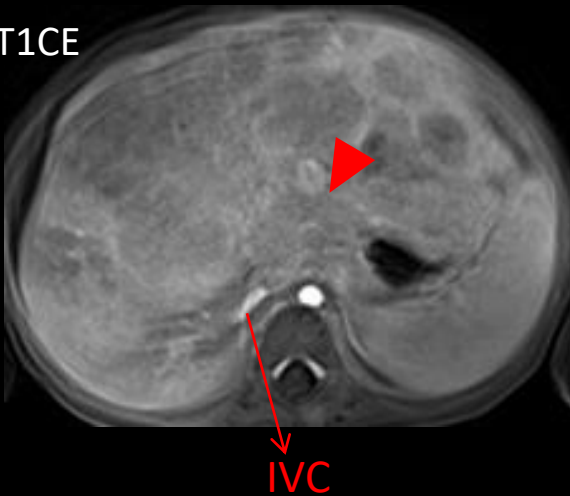
T2



T1



T1CE



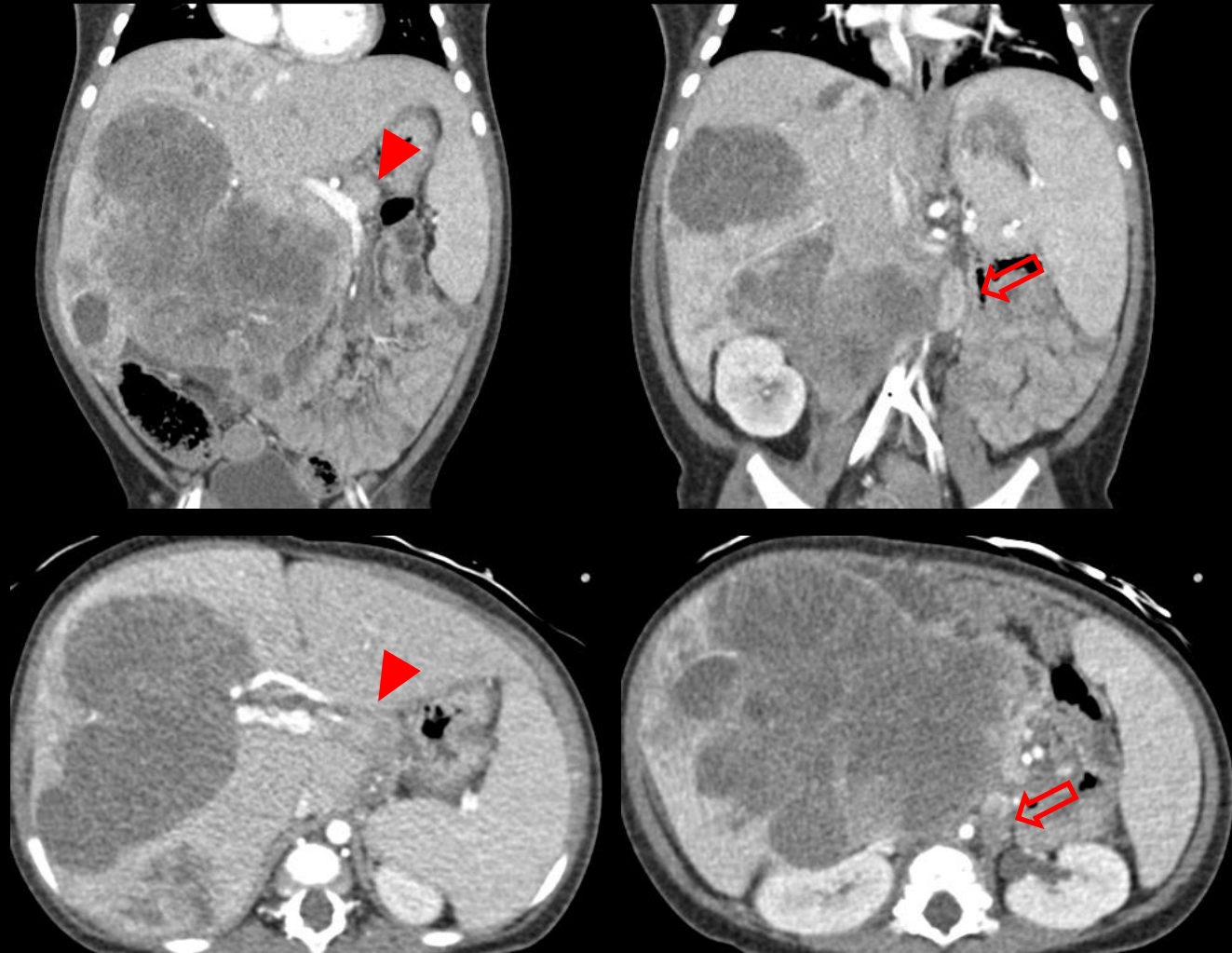
1/F. PRETEXT IV. Caudate lobe is involved by tumor (arrowhead).
Perihepatic ascites is present, however, there is no signal characteristics of blood; R (-).

Lymph node metastasis (N)



- Although lymph node metastasis is extremely **rare** in hepatoblastoma, one study (*European journal of cancer* 2000, 36, 1418-1425) reported that hilar lymph node enlargement is associated with reduced survival.
- Any of the following criteria:
 1. Lymph node with short-axis diameter $> 1\text{cm}$
 2. Portocaval lymph node with short-axis diameter $>1.5\text{cm}$
 3. Spherical lymph node shape with absent fatty hilum
- It should be noted that morphologic criteria, such as in criterion 3, are less sensitive for detection of metastases

Lymph node metastasis (clinically), N (+)



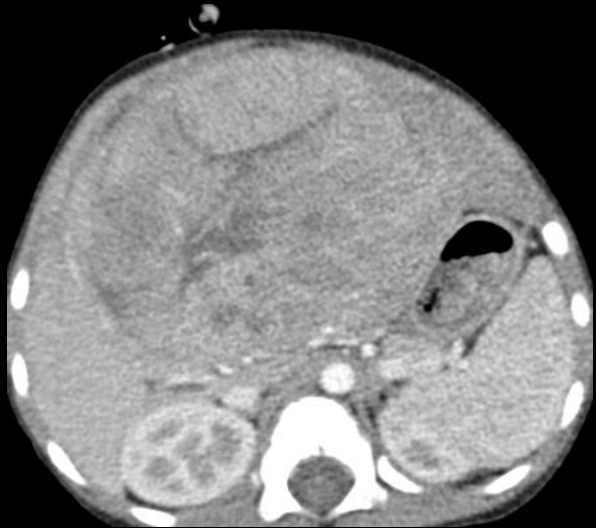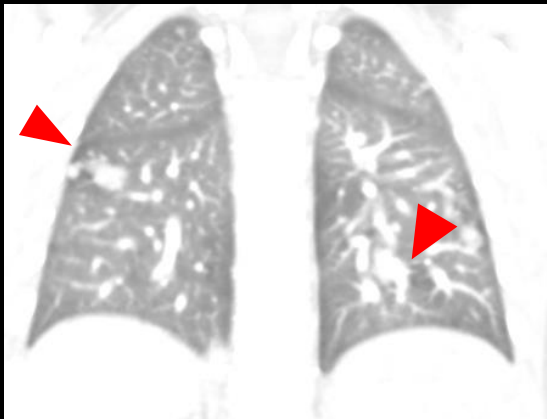
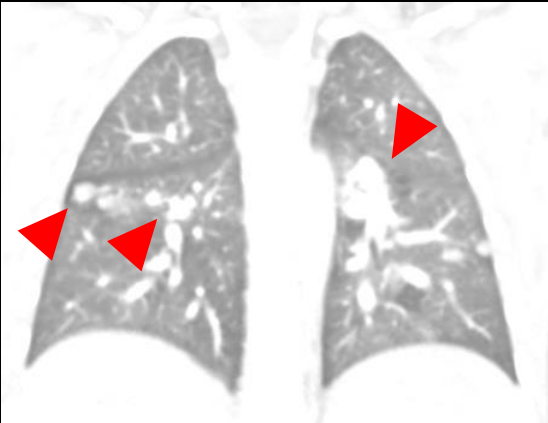
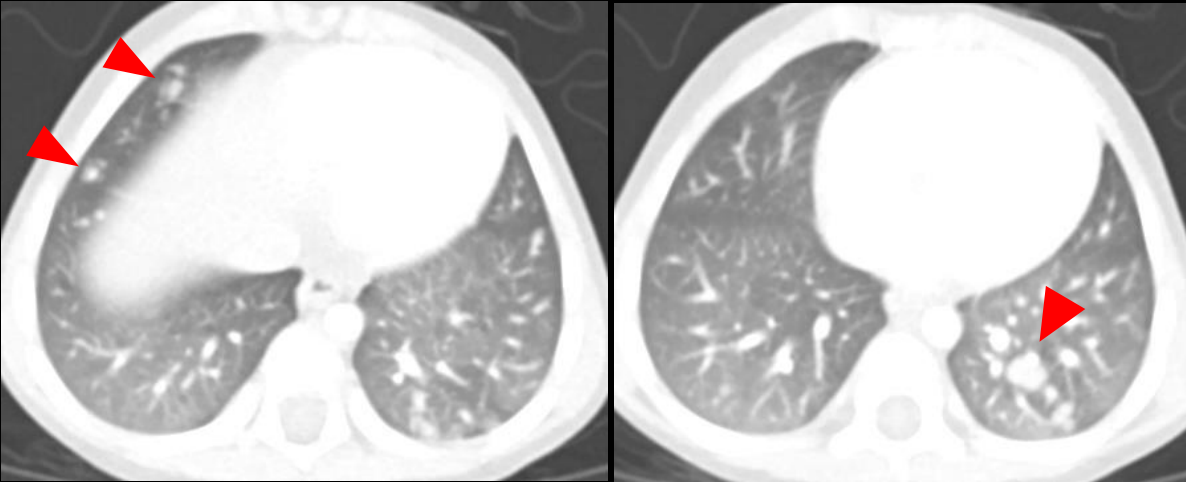
1/M. PRETEXT IV. Multiple enlarged LNs in periportal (arrowhead) and left para-aortic region (arrow). Surgical tumor resection or orthotopic liver transplantation were not performed in this patient, and lymph node metastasis is diagnosed clinically. The patient was treated with primary chemotherapy, but eventually died of refractory disease.

Distant metastasis (M)



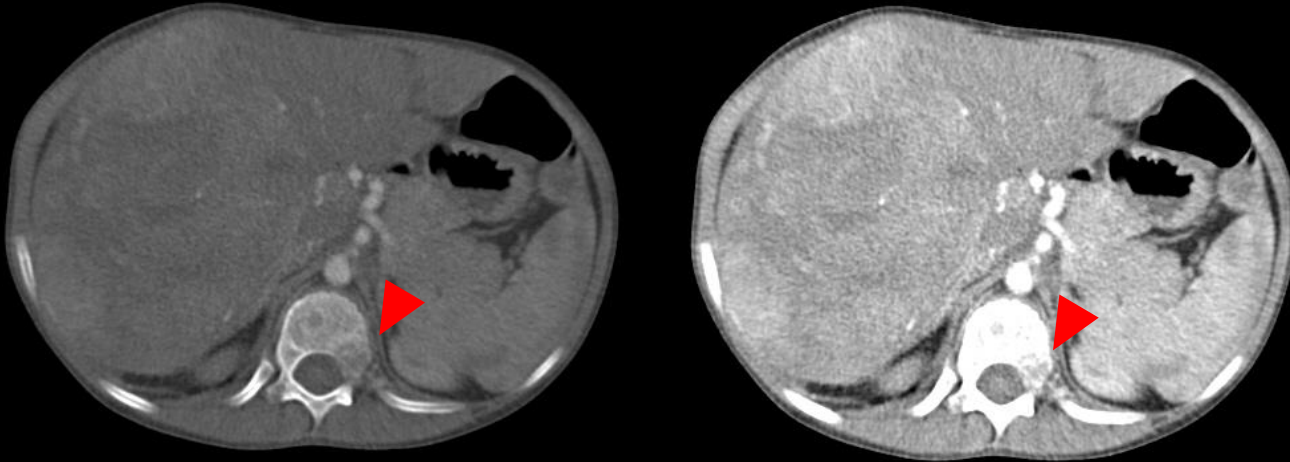
- The **lungs** are the m/c site of distant metastases in children with hepatoblastoma
- Metastases can occur to other locations: **bone and brain** metastases
- Any of the following criteria for pulmonary metastases
 1. Single non-calcified lung lesion with diameter $\geq 5\text{mm}$
 2. Two or more non-calcified lung lesions with each diameter $\geq 3\text{mm}$
- Distant metastasis is one of the **traditional poor prognostic factors** in hepatoblastoma
 - (European journal of cancer 2012, 48, 1543-1549) (Cancer 2002, 95, 172-182)

Distant metastasis to lungs, M (+)



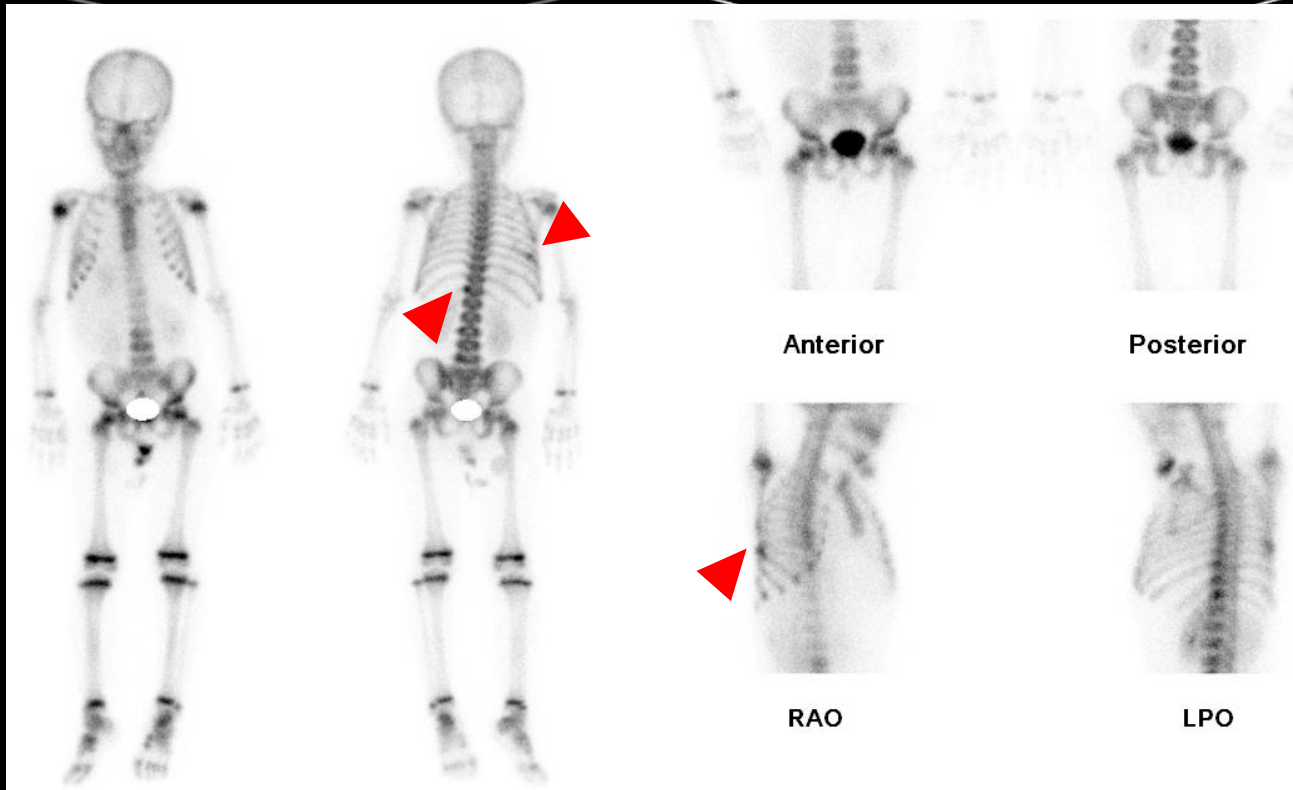
3/M. PRETEXT III.

Distant metastasis to bones, M (+)

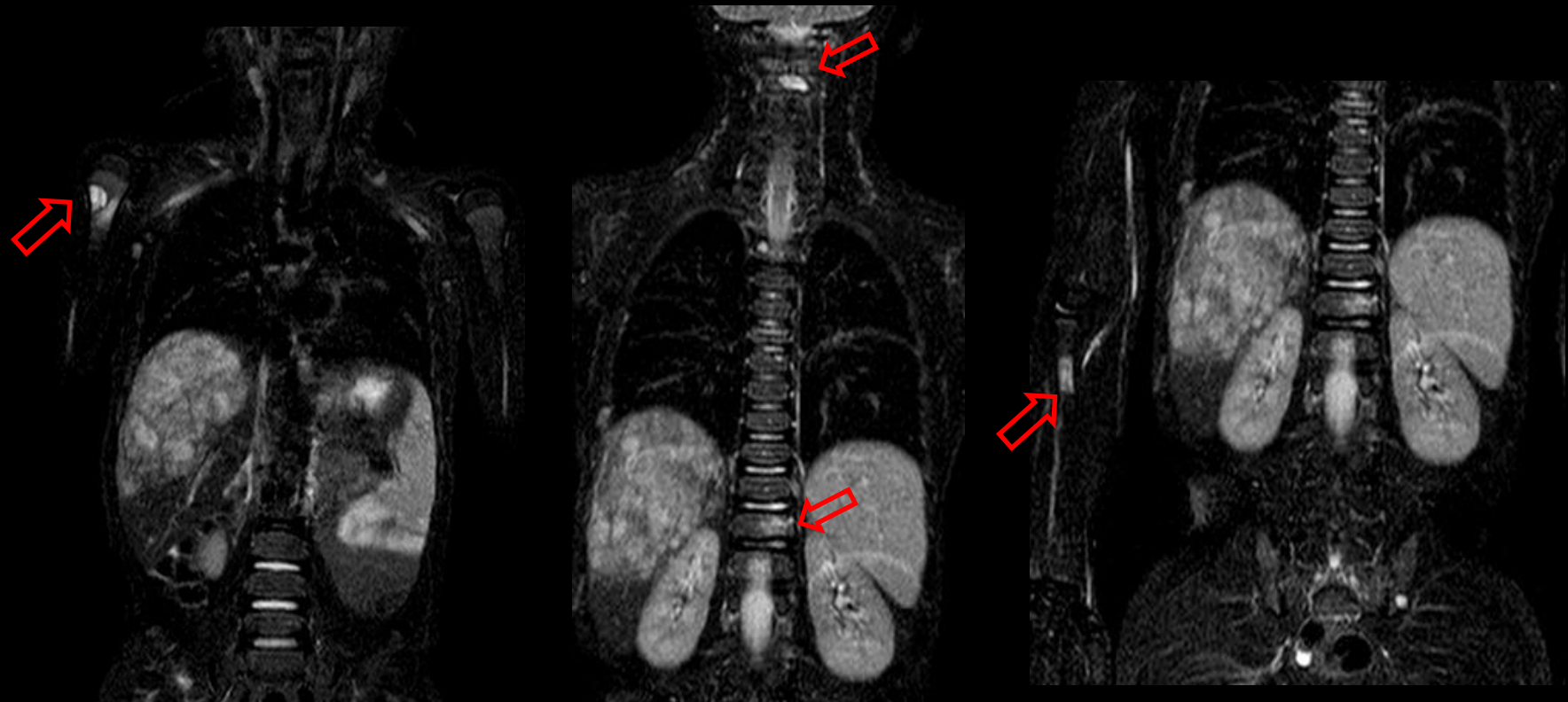

9/M. PRETEXT II.
Osteolytic bone metastasis is seen in T12 vertebral body on CT.

Bone scan reveals bone metastasis in right 8th rib in addition to T12 vertebral body.



Continued.



Three months later, bone metastases progressed with new involvement of right proximal humerus, C2 and L2 vertebral bodies, and right proximal radius.

- SUMMARY (1) -

PRETEXT groups	Definition
I	3 contiguous hepatic sections are free of tumor
II	2 contiguous hepatic sections are free of tumor
III	1 contiguous hepatic section is free of tumor
IV	Tumor affects all four hepatic sections (almost always multifocal or infiltrative)
Annotation factors	Positive definition
Hepatic venous/IVC involvement (V)	Any of the following criteria: <ul style="list-style-type: none"> - Tumor obliterates or encases all three hepatic veins or the intrahepatic IVC - Tumor thrombus in any hepatic vein or the intrahepatic IVC
Portal venous involvement (P)	Any of the following criteria: <ul style="list-style-type: none"> - Tumor obliterates or encases either both portal veins or the main portal vein - Tumor thrombus in either or both the right and left portal veins or the main portal vein

- SUMMARY (2) -

Annotation factors	Positive definition
Extrahepatic tumor extension (E)	<p>Any of the following criteria:</p> <ul style="list-style-type: none"> - Tumor crosses boundaries or tissue planes - Tumor is surrounded by normal tissue more than 180° <ul style="list-style-type: none"> - Peritoneal nodules: one nodule ≥ 10 mm or two or more nodules ≥ 5 mm
Multifocality (F)	Two or more separate hepatic tumors with normal liver tissue between the tumors
Tumor rupture (R)	Any findings of hemorrhage on imaging (Ultrasound, CT, MRI) Pathologically diagnosed after paracentesis/upfront resection
Caudate lobe (C)	Tumor involving the caudate lobe
Lymph node metastasis (N)	<p>Considered when any of the following morphologic criteria is met :</p> <ul style="list-style-type: none"> - Lymph node with short-axis diameter > 1 cm - Portocaval lymph node with short-axis diameter > 1.5 cm - Spherical lymph node shape with absent fatty hilum
Distant metastasis (M)	<p>Any of the following criteria for pulmonary metastasis:</p> <ul style="list-style-type: none"> - Single non-calcified lung lesion with diameter ≥ 5 mm - Two or more non-calcified lung lesions with each diameter ≥ 3 mm <p>Any metastases diagnosed via pathology</p>

-Thank you-